

research article

## Xanthogranulomatous cholecystitis remains a challenge in medical practice: experience in 24 cases

Mehmet Yildirim<sup>1</sup>, Ozgur Oztekin<sup>2</sup>, Fatih Akdamar<sup>1</sup>,  
Savas Yakan<sup>1</sup>, Hakan Postaci<sup>3</sup>

<sup>1</sup>Department of Surgery, <sup>2</sup>Department of Radiology, <sup>3</sup>Department of Pathology,  
Izmir Bozyaka Teaching and Research Hospital, Izmir, Turkey

**Background.** Xanthogranulomatous cholecystitis (XGC) is a rare, benign, chronic inflammatory disease of the gallbladder. Its importance lies in the fact that imaging studies and intraoperative appearance that may be confused with tumour of the gallbladder. This study aimed to evaluate pre-and intraoperative findings of XGC and to remind it in difficult cholecystectomy patients.

**Patients and methods.** The clinical data of 24 patients with XGC over a period of 7 years were analyzed retrospectively (mean age, 53 years (32-68) M/F ratio 1:1.4).

**Results.** The clinical symptoms were abdominal pain, nausea and jaundice in 79%, 62% and 12% of the patients. Preoperative ultrasonography for 24 patients revealed gallstone (95.8%) and bile sludge (8%). Pericholecystic fluid, polyp and tumour of the gallbladder was present in 20%, 4% and 4% of the patients. The gallbladder was thickened (>3mm) in 10 patients. On computed tomography, all patients showed abnormal findings. The intraoperative findings were as follows: gallstones (100%), chronic cholecystitis (54%), hydropic gallbladder, emphysematous gallbladder, adhesions of the gallbladder to adjacent organs and tumoural mass of gallbladder.

**Conclusions.** XGC is difficult to diagnose pre-or intraoperatively and remains a challenge in medical practice. The definitive diagnosis depends on the histopathologic examination.

*Key words:* xanthogranulomatous; cholecystitis; gallbladder

### Introduction

Xanthogranulomatous cholecystitis (XGC) is an uncommon inflammatory disease of the gallbladder characterized by the infil-

tration of plasma cells, lipid-laden histiocytes, and the proliferation of fibroblasts in the gallbladder wall.<sup>1</sup>

The term of xanthogranulomatous cholecystitis was initially proposed by Goodman and Ishak in 1981.<sup>2</sup> The pathogenesis of XGC is the rupture of Rokitansky-Aschoff sinuses and extravasation of bile into the muscular layer. The rupture of the serosa results in adhesion to the adjacent liver, duodenum, and transverse colon. Gallstones

Received 23 January 2009

Accepted 10 April 2009

Correspondence to: Dr Mehmet Yildirim, Atakent Mah.Bergama 2 Apt.Giris:32 Daire: 1, Bostanli, Izmir, Turkey; Phone: +90 232 3625692; Fax: +90 232 2614444; E-mail: mehmetyildi@gmail.com

may have an important role in the pathogenesis, since they appear to be present in most patients.<sup>3</sup>

The clinical and laboratory findings of cases with XGC are similar to those of acute or chronic cholecystitis.<sup>4</sup> The major intraoperative findings are frequently characterized by thickening of the gallbladder wall, tumour-like mass and adherence of the gallbladder to adjacent organs.<sup>5</sup> Patients with XGC are frequently misdiagnosed with imaging studies and even during the operation as having carcinoma of the gallbladder.

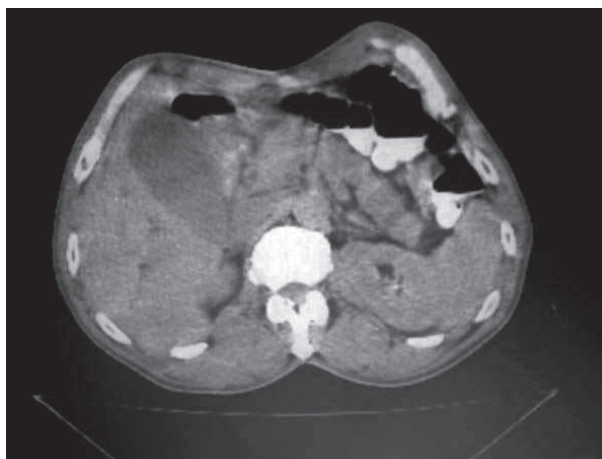
The aim of this study is to evaluate pre- and intraoperative findings of XGC and to remind it in difficult cholecystectomy patients.

### Patients and methods

Twenty four histologically confirmed cases of XGC were identified from the retrospective analysis of the patient records of 749 cholecystectomy operations over a period of 7 years (January 2000-April 2007). The study included 14 female and 10 male (male/female ratio 1:1.4) having a mean age of 53 years (range, 32- 68 years).

The clinical presentation, laboratory and radiological findings, surgical findings, histopathological characteristics, morbidity and mortality were investigated from the surgeon's registry.

All patients underwent preoperative ultrasound examination with 3 MHz transabdominal probe (General Electric Logic5 Pro, Milwaukee, Wisconsin, USA). CT examination was performed for 6 patients with Toshiba spiral CT Asteion. A standard abdominal MRI protocol was employed to one patient. All images were acquired using on 1.5 Tesla MR units. MR studies were performed on a 1.5 T unit (Achieva; Philips Medical Systems, Eindhoven, The Netherlands).



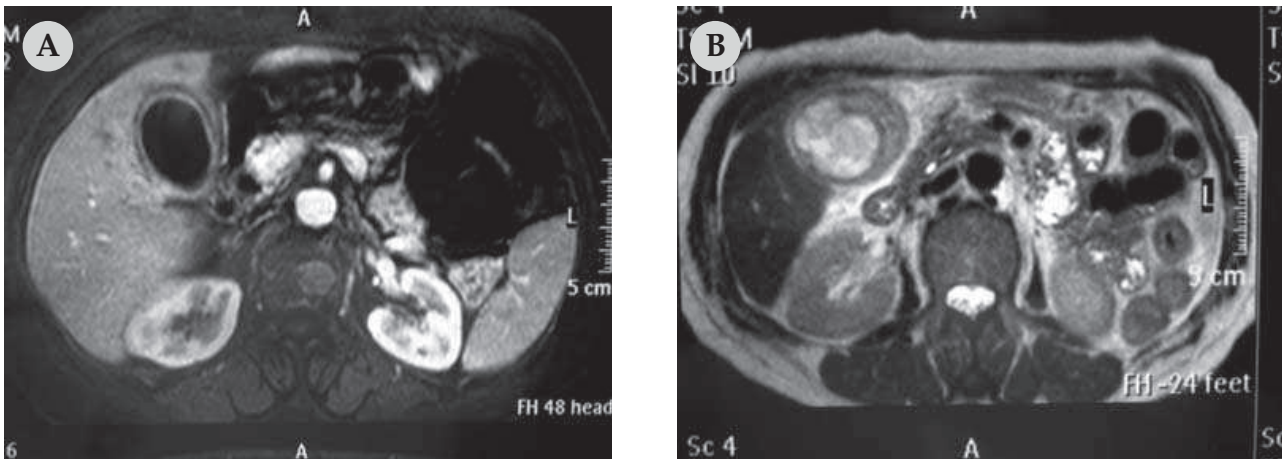
**Figure 1.** 59-year-old woman with xanthogranulomatous cholecystitis. Contrast-enhanced CT scan shows hydroptic gallbladder.

The US findings used for the diagnosis were presence of gallstone and bile sludge, pericholecystic fluid and thickness of the gallbladder wall. Thickening of the gallbladder wall was considered abnormal if it exceeded 3 mm to Kim *et al.*<sup>6</sup> The CT feature used for the diagnosis were presence of gallstones; increased thickness of the gallbladder wall (>3mm), loss of interface between the gallbladder and the liver; pericholecystic fluid; and choledocholithiasis. In one patient, a MRI study was made because of suspected gallbladder carcinoma in CT appearance.

The gallbladder was fixed with 10% formalin and specimens were stained with H and E. Descriptive statistics were used to describe the features of the data in our study.

### Results

The clinical symptoms were right hypochondrial pain in 19 (79%) patients, nausea in 15(62%) icteric sclera in three (12%), and fever in two (8%). Main signs included positive Murphy's sign, palpable mass in the right upper quadrant and yellow skin were found in 17 (70%), 24 (100%) and three (12%) patients.



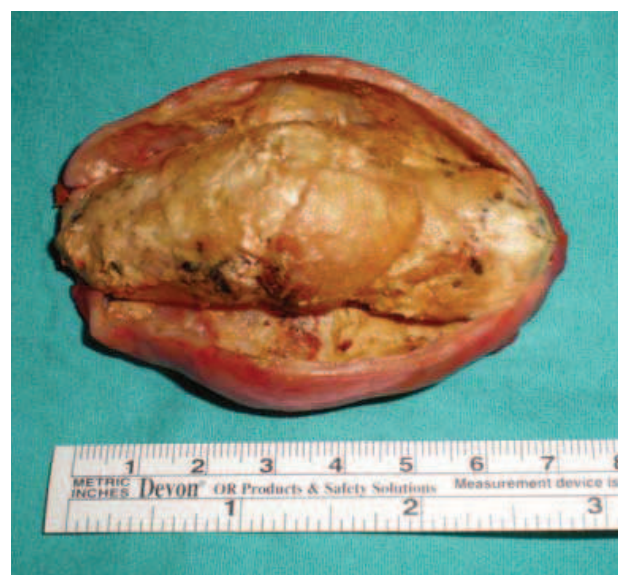**Figure 2.** Abdominal MR imaging demonstrating suspected gallbladder mass involving the liver in T1 weighted series(A), and a soft tissue mass in T2 weighted series (B).

Laboratory tests were within normal ranges except leucocytosis in five patients ( $>12.000/\mu\text{l}$ ), elevated ALT-AST and bilirubin levels were found in three patients in each group.

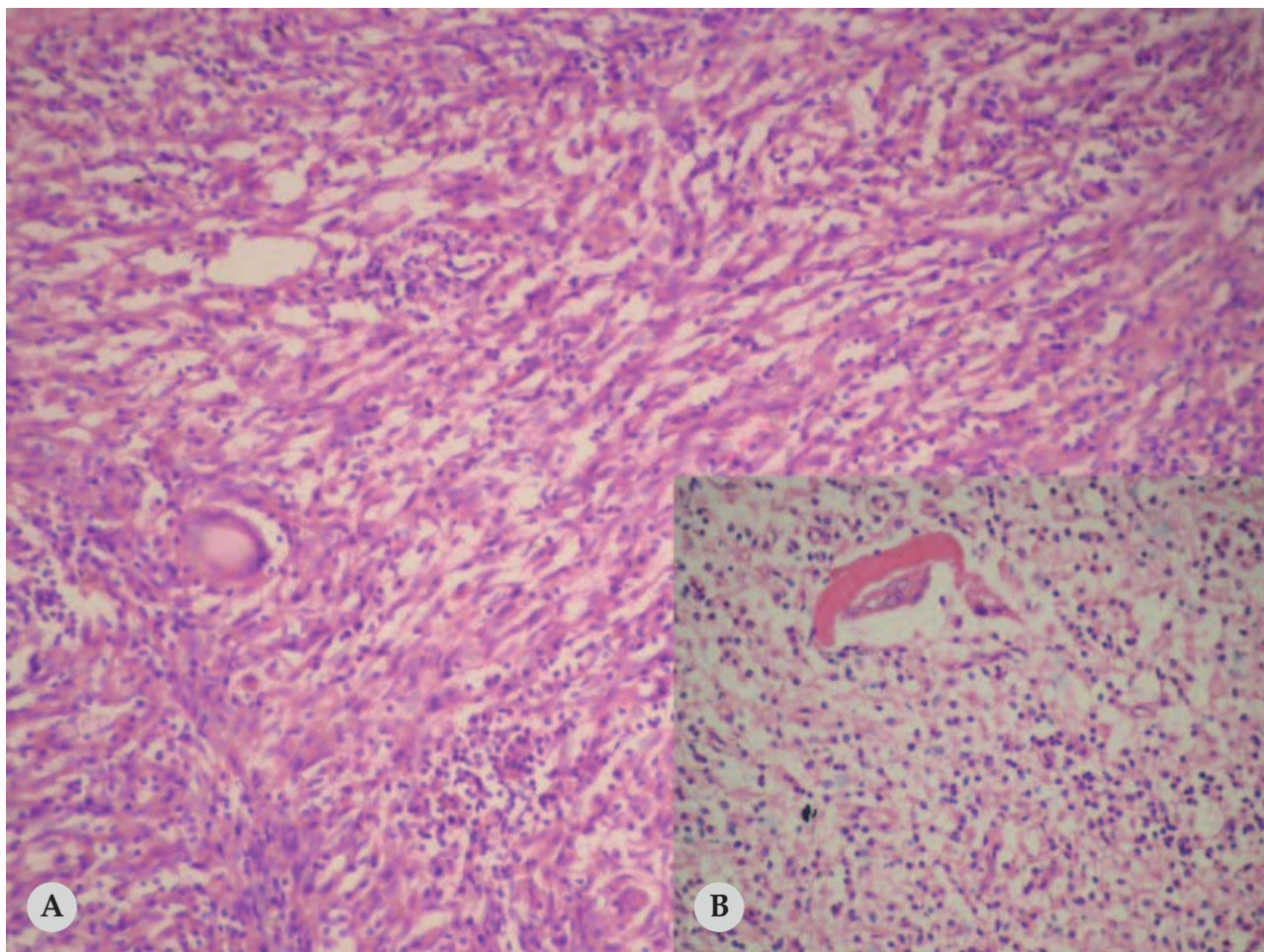
Preoperative US for 24 patients revealed gallstone in 23 (96%) patients, pericholecystic fluid in five (20%), bile sludge in two (8%), polyp of gallbladder in one (4%), and tumour of gallbladder in one (4%) patient. The gallbladder was thickened ( $>3\text{mm}$ ) in ten (41.6%) patients. Upper abdominal CT was performed in six (25%) patients. CT revealed hydrops of gallbladder in two (33.3%) patients (Figure 1), carcinoma of the pancreas also in two (33.3%) patients, pericholecystic abscess in one and one carcinoma of gallbladder. Thickening of the gallbladder wall was seen, more than 3 mm thick, in six patients. MRI showed suspected gallbladder cancer involving the liver in one patient (Figure 2A-B).

The intraoperative findings were as follows: chronic cholecystitis in 13 (54%), adhesions of the gallbladder to adjacent organs in four (adhesions to the transverse colon in two patients, the duodenohepatic ligament in one, and fundus of the gallbladder to abdominal wall in one), emphysematous gallbladder in three (perforation of the gallbladder in two patient and carcinoma

of the pancreas in one), hydrops of the gallbladder in two (carcinoma of the pancreas in one patient and enlarged gallbladder with a stone impacted in Hartmann's pouch in one), and tumoural mass of the gallbladder in two patients (Figure 3). The gallbladder stones were found in all patients. Furthermore, the frozen section was performed in one patient and malignancy was not found. The surgical treatment was elective open cholecystectomy in 23 (95.8%) patients and laparoscopic cholecystectomy (LC) in one (4.2%) patient. In one patient, who could not rule out the possibility of



**Figure 3.** Tumoural like deposits of xanthogranulomatous cholecystitis in surgical specimen.



**Figure 4.** Histiocytes, lymphocytes and giant cells present in a granulomatous focus of xanthogranulomatous inflammation. A; (HE X20) B; (HE X40)

carcinoma, cholecystectomy and wedge resection of adjacent liver was performed.

The postoperative complications were found in 7(29%) patients who included wound infection and pleural effusion in four and two patients, respectively. Acute renal failure developed in one patient with pancreas cancer. The average hospital stay time was 8 days (range, 3- 22 days). No mortality was seen.

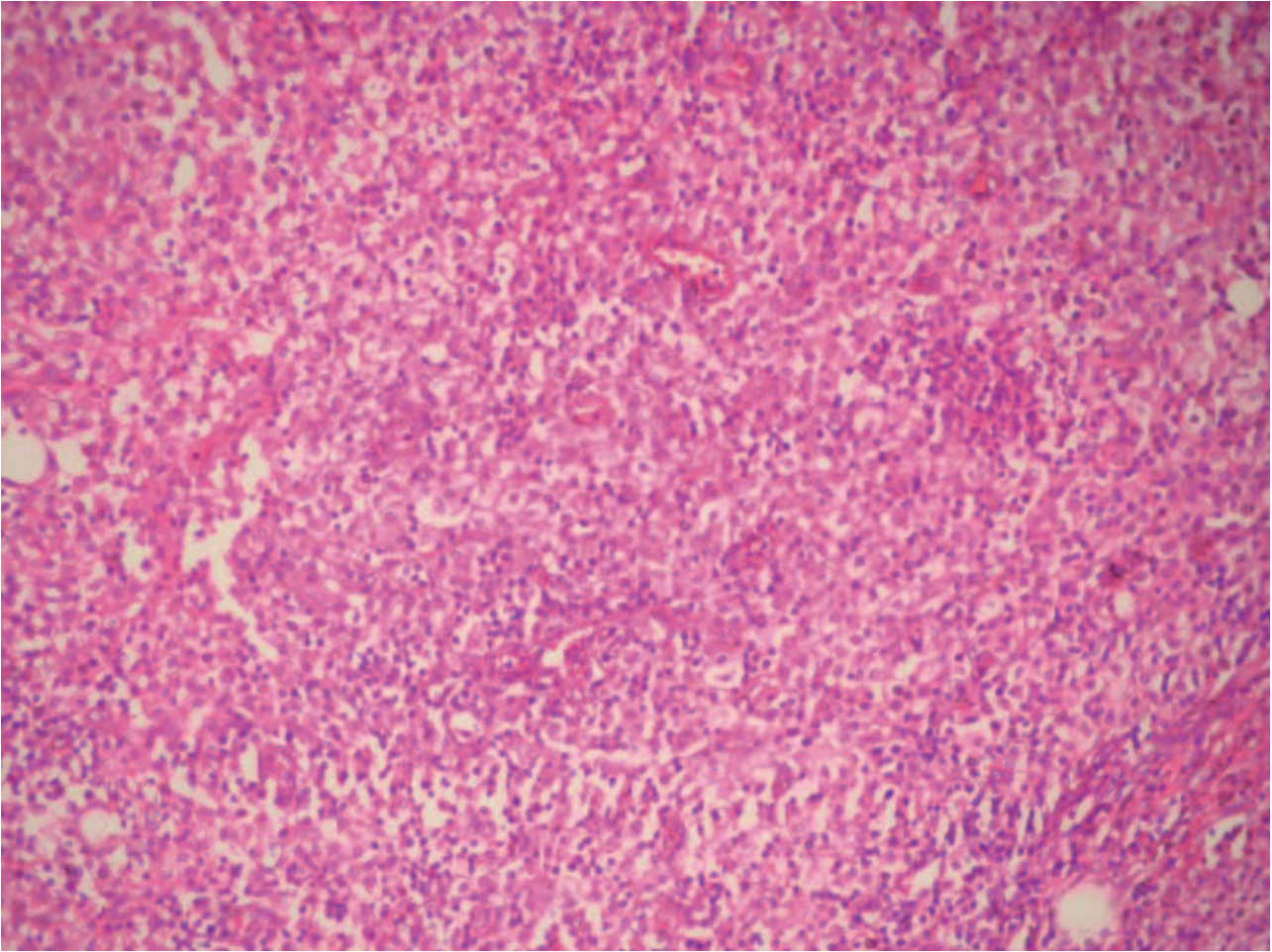
Histopathologically there were a focal or diffuse inflammatory process with xanthogranulomatous changes, histiocytosis and giant cells of foreign body in all patients (Figure 4-5). The examination of specimen showed gallstones in 24 (100%) patients, presence of sludge in 13 (54.4%), thickening gallbladder wall (>5 mm) in 15 (62%), dysplasia in four (16%) and mucosal

ulcers in three (12%). In addition four (16%) patients had lymphadenopathy which showed reactive lymphadenitis.

## Discussion

XGC was previously described as an uncommon form of chronic cholecystitis.<sup>7</sup> Christensen AH and Ishak KG initially described it as a pseudotumour with destructive type of gallbladder inflammation, pericholecystic infiltration, hepatic involvement and lymphadenopathy. In 1981 the term xanthogranulomatous cholecystitis was proposed in a review of 40 cases collected over a 10-year period.<sup>2</sup>

Even though the number of published cases is not large, XGC not as rare as gen-



**Figure 5.** Xanthogranulomatous inflammation of the gallbladder wall, characterized by histiocytes (HEx20).

erally believed.<sup>7</sup> In the literature, the incidence of XGC is reported to be 0.7% to 13.2%.<sup>8</sup> Higher incidence was reported from the Eastern countries.<sup>9-11</sup> In our series, the incidence of XGC was 4% among 749 patients who were operated on gallstone. XGC mostly affects middle-aged women and old persons between 60-70 years. Similar to the previous reports the mean age was 63 years in our study.<sup>12,13</sup> This suggests that age must be one of the significant factors in the development of the XGC. The male to female ratio range is from 2:1 to 1:2 in other series.<sup>14</sup> A study from India<sup>12</sup> reported a 1:9 male to female ratio while in our report male to female ratio was found 1:1.4. The different incidence of XGC may be due to misdiagnosis by clinicians.

Clinically, XGC does not have a typical presentation. Our patients were presented with right upper quadrant pain, nausea, fever, icterus and palpable mass; they are similar to acute or chronic cholecystitis. These clinical features are not specific for XGC and there was no difference between the patients with cholecystitis and gallbladder carcinoma.<sup>11,15</sup> We noted that all of the patients with these symptoms required an elective surgical procedure at first presentation. The association of XGC with a perforated gallbladder, abscess formation, enterobiliary fistula and Mirizzi syndrome were supported by increasing series.<sup>4,16</sup> In our series, these lesions were found in 16% patients. In one case, the adhesion of fundus to abdominal wall was considered as the potential of XGC for fistula formation.

The reported series support the existence of this comorbid factors seen in nearly 23% of patients.<sup>4</sup>

Preoperative biochemical tests or imaging studies are not suggestive of XGC.<sup>12</sup> Neither the liver function abnormalities nor the tumour markers (CEA, CA-19.9) are suggestive of XGC, although Adachi *et al.*<sup>17</sup> argued that serum level of CA-19.9 may be elevated in both carcinoma and XGC patients. It has been reported that thickening of the gallbladder, adhesion to neighbouring tissues or organs were specific findings to XGC, although there are other series that it is difficult to differentiate XGC from other lesions.<sup>18,19</sup> All these findings can be seen in acute cholecystitis; however, the presence of intramural low-attenuation nodules, preservation of mucosal lining and degree of enhancement of the gallbladder wall are suggestive of the XGC.<sup>18</sup> In our study none of the patients was diagnosed by radiologist as XGC with imaging findings. US misdiagnosed one case of XGC as carcinoma of the gallbladder (misdiagnose rate 4.3%), while CT misdiagnosed two cases of XGC as carcinoma (misdiagnose rate 33.3%). In this study, high misdiagnosis rate may be related to our insufficient experience for imaging findings of XGC. Chun *et al.*<sup>18</sup> concluded that a definitive diagnosis of gallbladder carcinoma is not possible with only imaging findings. In our study, thickening of the gallbladder wall was found in 24% and 46% patients with US and CT respectively. While thickening of the gallbladder wall was found in 62% of patients pathologically. This leads to the conclusion that thickening of the gallbladder wall in imaging findings itself is not a predictive factor in the diagnosis of XGC. Hatakenaka *et al.*<sup>20</sup> have demonstrated that MR imaging may play an important role in differentiating XGC from carcinoma in patients with a thickened gallbladder wall. In our series,

MR imaging did not differentiate XGC from gallbladder carcinoma.

In our series as in others reported in the literature, all patients had gallstones (100%), frequently sludge of bile (54%) or biliary obstruction (12%).<sup>4</sup> Its importance lies in the fact that gallstones can have an important role in the pathogenesis of XGC via extravasation of bile into the gallbladder wall. In contrary, in a series noted the presence of gallstone in only 85% of the XGC, which leads to the conclusion that the presence of gallstone is only an associated condition and not the cause of the inflammatory process.<sup>21</sup> The small ulcerations in the mucosa reported to be a precipitating factor in other studies.<sup>7,8</sup> The extravasation of bile causes that fibrous reaction and scarring healing within the gallbladder wall, response due to thickening of the gallbladder wall. The ulcerations in the mucosa were found pathologically in 12% of our patients.

Open cholecystectomy is the first choice for XGC, either complete or partial.<sup>14</sup> In our series, single cholecystectomy was performed on 23 patients and cholecystectomy with partial hepatic wedge resection on one patient. LC may be contraindicated in XGC because of a high incidence of complications. According to the study carried by Guzmán-Valdivia G, LC was not completed due to difficulty in dissecting the gallbladder and converted into the open procedure in 80% of the patients diagnosed as XGC.<sup>21</sup> The necessity of radical surgery is not cleared with extra-gallbladder involvement.<sup>4</sup> The intraoperative frozen section or fine needle aspiration has been suggested to confirm the diagnosis of XGC.<sup>9</sup> The frozen section is valuable when there is no invasion of pericholecystic organs. In our series, the frozen section was used (negative result) in a case with an extensive invasion of liver. We believe it was not change the approach of surgeon. Nevertheless, in the patients with negative results, the radical

surgery can be performed due to the coexistence of XGC and carcinoma of the gallbladder. On the other hand, studies report that the radical surgery may be associated with a high perioperative morbidity.<sup>22</sup>

Although XGC is a benign disease, patients usually have a longer hospital stay with a postoperative complications.<sup>4</sup> In our study, complications occurred in 7(29%) patients including wound infection, pleural effusion and renal failure related to hepatorenal failure. Complications were reported including leakage of bile and bile peritonitis which largely related to the difficulty in cholecystectomy.<sup>9</sup> The complications are thus related more to the technical difficulty in stripping the gallbladder, the mode of the operation and the clinical condition of the patient than to the disease itself.

### Conclusions

The pre- or intraoperative differential diagnosis of XGC from other gallbladder diseases remains a challenge in medical practice. The presence of firm adhesions of the gallbladder to neighbouring organs and tissues, thickened gallbladder wall, together with gallstone in a patient with chronic disease, is highly suggestive of XGC. The definitive diagnosis depends on the histopathologic examination. XGC can be treated successfully with an accurate diagnosis and proper operation.

### References

- Houston JP, Collins MC, Cameron I, Reed MWR, Parsons MA, Roberts KM. Xanthogranulomatous cholecystitis. *Br J Surg* 1994; **81**: 1030-2.
- Goodman ZD, Ishak KG. Xanthogranulomatous cholecystitis. *Am J Surg Pathol* 1981; **5**: 653-9.
- Benbow EW. Xanthogranulomatous cholecystitis. *Br J Surg* 1990; **77**: 255-6.
- Yang T, Zhang BH, Zhang J, Zhang YJ, Jiang XQ, Wu MC. Surgical treatment of xanthogranulomatous cholecystitis: experience in 33 cases. *Hepatobiliary Pancreat Dis Int* 2007; **6**: 504-8.
- Spinelli A, Schumacher G, Pascher A, Lopez-Hanninen E, Al-Abadi H, Benckert C, et al. Extended surgical resection for xanthogranulomatous cholecystitis mimicking advanced gallbladder carcinoma: a case report and review of literature. *World J Gastroenterol* 2006; **12**: 2293-6.
- Kim PN, Ha HK, Kim YH, Lee MG, Kim MH, Auh YH. US findings of xanthogranulomatous cholecystitis. *Clin Radiol* 1998; **53**: 290 -2.
- Ros PR, Goodman ZD. Xanthogranulomatous cholecystitis versus gallbladder carcinoma. *Radiology* 1997; **203**: 10-2.
- Kwon AH, Matsui Y, Uemura Y. Surgical procedures and histopathologic findings for patients with Xanthogranulomatous cholecystitis. *J Am Coll Surg* 2004; **199**: 204-10.
- Karabulut Z, Besim H, Hamamci O, Bostano lu S, Korkmaz A. Xanthogranulomatous cholecystitis. Retrospective analysis of 12 cases. *Acta Chir Belg* 2003; **103**: 297-9.
- Dixit VK, Prakash A, Gupta A, Pandey M, Gautam A, Kumar M, et al. Xanthogranulomatous cholecystitis. *Dig Dis Sci* 1998; **43**: 940-2.
- Roberts KM, Parsons MA. Xanthogranulomatous cholecystitis: clinicopathological study of 13 cases. *J Clin Pathol* 1987; **40**: 412-7.
- Belagué C, Targarona EM, Sugra es G, Rey MJ, Arce Y, Viella P, et al. Xanthogranulomatous cholecystitis simulating gallbladder neoplasm: therapeutic implications. *Gastroenterol Hepatol* 1996; **19**: 503-6.
- Eriguchi N, Aoyagi S, Tamae T, Kanazawa N, Nagashima J, Nishimura K et al. Xanthogranulomatous cholecystitis. *Med J* 2001; **48**: 219-21.
- Guzmán-Valdivia G. Xanthogranulomatous cholecystitis: 15 years' experience. *World J Surg* 2004; **28**: 254-7.
- Wang D, Yamakawa T, Fukuda N, Maruno K, Ushigome S, Ishiyama J. Xanthogranulomatous cholecystitis: report of a case and literature review on clinical differentiating factors from gallbladder carcinoma. *Digest Endoscopy* 2004; **16**: 143-7.
- Benbow EW. Xanthogranulomatous cholecystitis. *Br J Surg* 1990; **77**: 255-6.

17. Adachi Y, Iso Y, Moriyama M, Kasai T, Hashimoto H. Increased serum CA 19-9 in patients with xanthogranulomatous cholecystitis. *Hepatogastroenterol* 1998; **45**: 77-80.
18. Chun KA, Ha HK, Yu ES, Shinn KS, Kim KW, Lee DH, et al. Xanthogranulomatous cholecystitis: CT features with emphasis on differentiation from gall-bladder carcinoma. *Radiology* 1997; **203**: 93-7.
19. Para A, Acinas O, Bueno J, Güzemes A, Fernandez MA, Farinas MC. Xanthogranulomatous cholecystitis clinical, sonographic, and CT findings in 26 patients. *AJR* 2000; **174**: 979-83.
20. Hatakenaka M, Adachi T, Matsuyama A, Mori M, Yoshikawa Y. Xanthogranulomatous cholecystitis: importance of chemical-shift gradient-echo MR imaging. *Eur Radiol* 2003; **13**: 2233-5.
21. Guzmán-Valdivia G. Xanthogranulomatous cholecystitis in laparoscopic surgery. *J Gastrointest Surg* 2005; **9**: 494-7.
22. Srinivas GN, Sinha S, Ryley N, Houghton PW. Perfidious gallbladders - a diagnostic dilemma with xanthogranulomatous cholecystitis. *Ann R Coll Surg Engl* 2007; **89**: 168-72.