

^{18}F -FET and ^{18}F -FCH uptake in human glioblastoma T98G cell lines

Marco Giovanni Persico¹, Federica Eleonora Buroni¹, Francesca Pasi², Lorenzo Lodola¹, Carlo Aprile¹, Rosanna Nano³, Marina Hodolic⁴

¹ Department of Oncohaematology, Nuclear Medicine Unit, IRCCS San Matteo Hospital Foundation, Pavia, Italy

² Department of Oncohaematology, Radiotherapy Unit, IRCCS San Matteo Hospital Foundation, Pavia, Italy

³ Department of Biology and Biotechnology "Lazzaro Spallanzani", University of Pavia, Pavia, Italy

⁴ Nuclear medicine research department, Iason, Graz, Austria

Radiol Oncol 2016; 50(2): 153-158.

Received 26 November 2015

Accepted 18 March 2016

Correspondence to: Lorenzo Lodola, Fondazione IRCCS Policlinico San Matteo, V. le Golgi 19, 27100 Pavia, Italy. Phone: +39 038 250 1666; Fax: +39 0382501669; E-mail: l.lodola@smatteo.pv.it

Disclosure: No potential conflicts of interest were disclosed.

M.G.P., F.E.B. and F.P. have contributed equally.

Background. Despite complex treatment of surgery, radiotherapy and chemotherapy, high grade gliomas often recur. Differentiation between post-treatment changes and recurrence is difficult. ^{18}F -methyl-choline (^{18}F -FCH) is frequently used in staging and detection of recurrent prostate cancer disease as well as some brain tumours; however accumulation in inflammatory tissue limits its specificity. The ^{18}F -ethyl-tyrosine (^{18}F -FET) shows a specific uptake in malignant cells, resulting from increased expression of amino acid transporters or diffusing through the disrupted blood-brain barrier. ^{18}F -FET exhibits lower uptake in macrophages and other inflammatory cells. Aim of this study was to evaluate ^{18}F -FCH and ^{18}F -FET uptake by human glioblastoma T98G cells.

Material and methods. Human glioblastoma T98G or human dermal fibroblasts cells, seeded at a density to obtain 2×10^5 cells per flask when radioactive tracers were administered, grew adherent to the plastic surface at 37°C in 5% CO_2 in complete medium. Equimolar amounts of radiopharmaceuticals were added to cells for different incubation times (20 to 120 minutes) for ^{18}F -FCH and ^{18}F -FET respectively. The cellular radiotracer uptake was determined with a gamma counter. All experiments were carried out in duplicate and repeated three times. The uptake measurements are expressed as the percentage of the administered dose of tracer per 2×10^5 cells. Data (expressed as mean values of % uptake of radiopharmaceuticals) were compared using parametric or non-parametric tests as appropriate. Differences were regarded as statistically significant when $p < 0.05$.

Results. A significant uptake of ^{18}F -FCH was seen in T98G cells at 60, 90 and 120 minutes. The percentage uptake of ^{18}F -FET in comparison to ^{18}F -FCH was lower by a factor of more than 3, with different kinetic curves. ^{18}F -FET showed a more rapid initial uptake up to 40 minutes and ^{18}F -FCH showed a progressive rise reaching a maximum after 90 minutes.

Conclusions. ^{18}F -FCH and ^{18}F -FET are candidates for neuro-oncological PET imaging. ^{18}F -FET could be the most useful oncological PET marker in the presence of reparative changes after therapy, where the higher affinity of ^{18}F -FCH to inflammatory cells makes it more difficult to discriminate between tumour persistence and non-neoplastic changes. Additional studies on the influence of inflammatory tissue and radionecrotic cellular components on radiopharmaceutical uptake are necessary.

Key words:

Introduction

The human brain is made up of approximately 100 billion nerve cells. Already in 19th century

there was a statement that nervous system is held together by specific cells called glia (in Greek language: glia=glue). More than insulating one neuron from another and prevent neuronal injury, glia

supply oxygen and nutrients to neurons, destroy pathogens and remove dead neurons. In the brain, glial cells are more numerous than nerve cells (ratio of app. 3:1).¹

Approximately 30% of all brain tumours and app. 80% of malignant ones arise from glial cell (gliomas). Different oncogenes and genetic disorders are most commonly mentioned as causes of gliomas. Despite complex treatment of surgery, radiotherapy and chemotherapy, high grade gliomas almost always recur.^{2,3} Before additional systemic or local therapies are performed, precise localization of recurrent tumour is essential. Differentiation between postsurgical, postradiotherapy changes and recurrent tumour is still a difficult diagnostic task.

Magnetic resonance imaging (MRI) is well established imaging modality for diagnosis of recurrent disease in patients with gliomas.^{4,6} ^{18}F -fluorodeoxyglucose (^{18}F -FDG) Positron Emission Tomography (PET) in brain tumours was the first application of this modality in oncology^{7,8}, however because of the high physiologic glucose uptake of normal brain tissue, ^{18}F -FDG did not gain widespread use in brain tumours imaging.^{9,10}

PET imaging with [^{11}C]- and [^{18}F]-labelled choline derivatives is frequently used in the staging and detection of recurrent prostate cancer disease due to the increased choline kinase expression in this malignancy. Moreover, choline kinase dysregulation can be frequently found, not only in prostate cancer cells but in a large panel of human tumours such as lung, colorectal, and brain tumours.¹¹⁻¹³ Following intravenous injection of choline derivatives in rats and mice, the brain uptake is less than 0.2% of the injected dose.¹⁴ However, choline accumulation in inflammatory tissue limits the specificity of choline PET for tumour detection.¹⁵

In the last decades, radiolabelled amino acids are attracting increasing interest in nuclear medicine because amino acid tracers appear to be more specific for brain tumour imaging than tracers like [^{11}C]- and [^{18}F]-labelled choline derivatives or 3,4-Dihydroxy-6-[^{18}F]fluoro-L-phenylalanine (^{18}F -DOPA). Results on cellular uptake of O-(2-[^{18}F]fluoroethyl)-L-tyrosine (^{18}F -FET) has been studied in vitro and in vivo already in the 1960's.¹⁶ The uptake mechanism of ^{18}F -FET in malignantly transformed cells can either be active or probably result from increased expression of amino acid transporters or passive, whereby the accumulation is slightly higher in tumour tissue with a disrupted blood-brain barrier. In contrast to ^{18}F and ^{11}C -choline, ^{18}F -FET exhibits lower uptake in macrophages and other inflammatory cells.^{17,18} Also ^{11}C -methionine, la-

belled amino acid for PET imaging of central nervous system tumours, showed very good results. But because of short half-life of ^{11}C (20.4 min), this tracer can be used just in the centres with on-site cyclotron. In the last years many articles supported statement that ^{18}F -FET PET/CT is valuable modality for individual treatment decision in patients with low grade gliomas.¹⁹⁻²⁴ The T98G cells are the most radio resistant cell line available derived from a human glioblastoma multiforme tumour.²⁵ T98G are arrested in G1 phase under stationary phase conditions, so they also exhibit the transformed characteristics of anchorage independence and immortality.²⁶

In our previous study²⁷, we compared the uptake of ^{18}F -FCH and ^{18}F -FDG by T98G cells and fibroblasts; also for evaluation its influence on cellular radiopharmaceutical uptake competition experiments with cold choline were performed.

Aim of this study was to evaluate ^{18}F -FCH and ^{18}F -FET uptake on T98G cell lines derived from a human glioblastoma multiforme tumour.

Material and methods

Cell lines

Human glioblastoma T98G cells were purchased from the European Collection of Cell Cultures (ECACC, Salisbury, UK) and cultured in Eagle's Minimum Essential Medium (EMEM, Euroclone SpA, MI, Italy) supplemented with 10% fetal bovine serum, 100 units/mL penicillin/streptomycin, 2 mM L-glutamine and 0.01% sodium pyruvate at 37°C in a humidified atmosphere of 5% CO_2 in air. Human dermal fibroblasts were used as non-pathological control cell types. Primary cultures of human dermal fibroblasts were derived from biopsies of healthy donors after obtaining informed consent. Primary cultures of fibroblasts were cultured in Dulbecco's modified Eagle's medium (DMEM, Euroclone SpA, MI, Italy) supplemented with 10% fetal bovine serum, 100 units/mL penicillin, 100 g/mL streptomycin, 2 mM L-glutamine at 37°C in a humidified atmosphere of 5% CO_2 in air. Stock cultures of both cell lines were maintained in exponential growth as monolayers in 25 cm² Corning plastic tissue-culture flasks (Sigma-Aldrich, St Louis, MO, USA).

Radioactive tracer incubation

^{18}F -FCH and ^{18}F -FET were obtained from IASON GmbH (Graz-Seiersberg, Austria). Synthesis of ^{18}F -FCH was performed as follows: The precu-

ator was reacted with ^{18}F and the intermediate was evaporated via a solid phase cartridge. After the gas phase reaction, the product was trapped and purified by solid phase cartridges and passed through a sterilized filter, synthesis of ^{18}F -FET was performed as follows: The precursor (in acetonitrile) was reacted with ^{18}F . After ^{18}F incorporation, acetonitrile was removed under pressure, and hydrolysis was carried out with 1 M HCl. The final solution was neutralized and purified by solid phase cartridges and passed through a sterilized filter.

Cells, seeded at a density to obtain 2×10^5 cells per flask when radioactive tracers were administered, grew adherent to the plastic surface at 37°C in 5% CO_2 in complete medium. Radioactive tracer experiments were performed 20-22 hours post-seeding in order to use the cells in the exponential phase of growth. The medium was renewed before performing studies. Cells were incubated at 37°C with 100 kBq (100 μL) equimolar amounts of ^{18}F -FCH or ^{18}F -FET, added in 2 mL of medium in each flask for varying incubation times (20, 40, 60, 90, 120 min for ^{18}F -FCH; 20, 40, 60, 80, 100, 120 min for ^{18}F -FET) under 5% CO_2 gaseous conditions. For experiments with ^{18}F -FCH and ^{18}F -FET, radiotracer incubation was done in complete medium. Control samples underwent the same procedure as other samples, but they were incubated with 100 μL of saline instead of a radiotracer.

Cell kinetic studies and uptake evaluation

The cellular radiotracer uptake was determined with a $3 \times 3''$ NaI(Tl) pinhole 16×40 mm gamma counter (Raytest, Straubenhardt, Germany). All measurements were carried out under the same counting position along with a standardized source to verify the counter's performance and the data were corrected for background and decay. Total radioactivity was counted when the radiotracer was added to the medium in each flask (time 0). After 20, 40, 60, 90, 120 min for ^{18}F -FCH and 20, 40, 60, 80, 100, 120 min for ^{18}F -FET from time 0, the medium was harvested, the cells were rapidly washed three times with 1 mL of phosphate-buffered saline (PBS) and radiopharmaceutical uptake for each sample was assessed. All experiments were carried out in duplicate and repeated three times. The uptake measurements are expressed as the percentage of the administered dose of tracer per 2×10^5 cells after correction for negative control uptake (flasks containing no cells with complete medium and incubated with radiopharmaceutical).

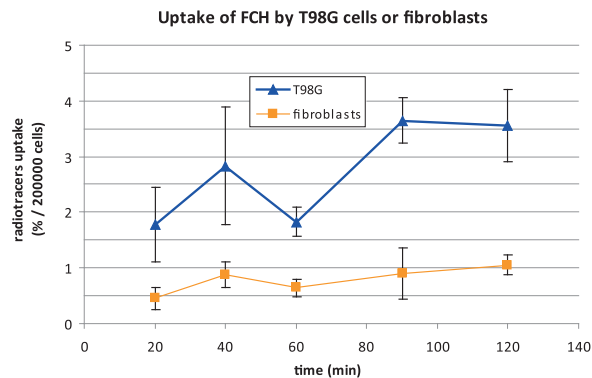


FIGURE 1. Uptake of ^{18}F -methyl-choline (^{18}F -FCH) by T98G cells and human dermal fibroblasts.

Cell viability assay

At the end of quantitative gamma spectrometry, adherent cells were harvested with 1% trypsin-EDTA solution and supernatants with adherent cells were counted with Burker's chamber. Trypan Blue dye assay was performed to assess cell viability as standard protocol.

Statistical analysis

In vitro binding experiments were conducted in duplicate and repeated three times. Data (expressed as mean values of % uptake of radiopharmaceuticals) were compared using parametric or non-parametric tests as appropriate. Differences were regarded as statistically significant when $p < 0.05$. All values are expressed as mean values with confidence interval CI 95% and report the uptake of radiotracers as a function of the incubation period. All values are shown as a percentage of the administered dose per 200,000 cells (mean \pm CI 95%). Therefore, if error bars on the Y axis do not overlap, the two points are considered significantly different.

Results

Radiopharmaceuticals binding assay

A significant uptake of ^{18}F -FCH was seen in T98G cells after 60 minutes, with a percentage of uptake of $1.8 \pm 0.3\%$, $3.6 \pm 0.4\%$ and $3.6 \pm 0.6\%$ at 60, 90 and 120 min respectively. Human dermal fibroblasts did not seem to accumulate ^{18}F -FCH specifically; at each incubation time the percentage of the administered dose in the cells was lower than 1%. Human dermal fibroblast uptake was significantly lower than in the T98G cell uptake in all incubation times (Figure 1).

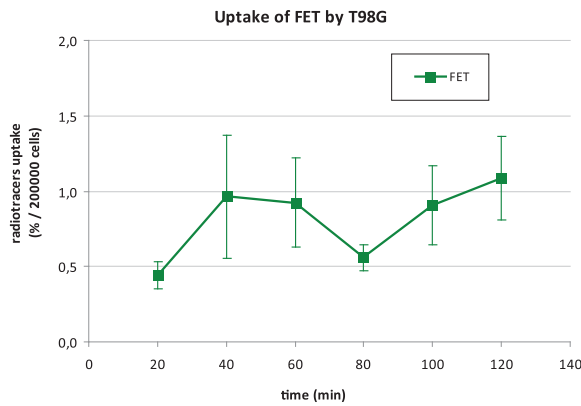


FIGURE 2. Uptake of ^{18}F -ethyl-tyrosine (^{18}F -FET) by T98G cells.

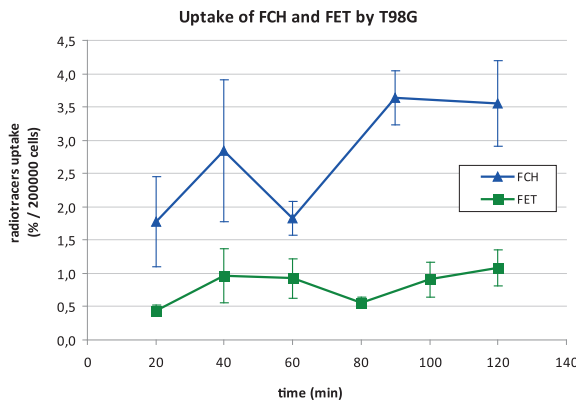


FIGURE 3. Uptake of ^{18}F -methyl-choline (^{18}F -FCH) and ^{18}F -ethyl-tyrosine (^{18}F -FET) by T98G cells.

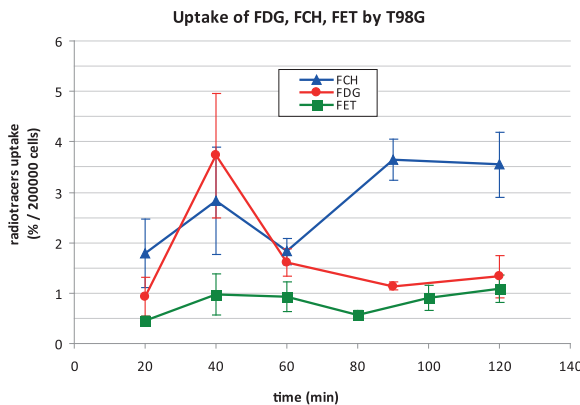


FIGURE 4. Uptake of ^{18}F -fluorodeoxyglucose (^{18}F -FDG), ^{18}F -methyl-choline (^{18}F -FCH) and ^{18}F -ethyl-tyrosine (^{18}F -FET) by T98G cells.

Figure 2 shows the kinetic uptake of ^{18}F -FET by T98G cells. Despite the trend represented by the curve, the uptake is quite low in terms of radiotracer uptake (% / 200000 cells).

Figure 3 shows that the uptake by T98G cells is increased for ^{18}F -FCH in comparison to ^{18}F -FET. The trend of the two kinetic curves are quite different: the uptake by T98G cells is increased for ^{18}F -FCH over ^{18}F -FET and the accumulation kinetic is not superimposable (see discussion).

Figure 4 illustrates the comparison of ^{18}F -FDG (data derived from our previous study²⁷, ^{18}F -FCH and ^{18}F -FET uptake in T98G cells. At 40 min and at the following time points there is not overlapping of the confidence bars for ^{18}F -FDG and ^{18}F -FET, and the ^{18}F -FET uptake is always lower than ^{18}F -FDG. ^{18}F -FCH uptake at time points after 60 min, is higher in comparison to the other radiopharmaceuticals.

As a negative control, flasks containing medium without cells were incubated under the same conditions and did not show a significant uptake of radiotracers.

Cell viability

Exposure to the gaseous mixture was maintained throughout the experiment and the cells' viability was calculated to be approximately 90% under all experimental conditions (data not shown).

Discussion

Our research data on T98G human glioblastoma cell lines underscores the affinity of ^{18}F -FET for neoplastic tissue, confirming its potential as a viable oncological PET marker. However, two aspects need to be discussed.

The percentage uptake of ^{18}F -FET in comparison to ^{18}F -FCH was lower by a factor of more than 3. Furthermore, both tracers showed a lower uptake of radioactivity under 60 minutes in comparison to values previously reported for ^{18}F -FDG.²

A thorough literature search did not find any studies with direct comparisons between ^{18}F -FCH and ^{18}F -FET uptake in glioma cell cultures. However, papers related to in vivo uptake in experimental rat gliomas indicate a higher accumulation of ^{18}F -FET in terms of Standard Uptake Value (SUV) as seen in both transplanted C6²⁸ or F98 glioma models^{29,30} in comparison to radio-labelled choline. Despite the different amounts of ^{18}F -FCH and ^{18}F -FET taken up by the same cell culture, the in vitro kinetic uptake is quite similar. ^{18}F -FET did show a more rapid initial uptake up to 40 minutes and ^{18}F -FCH showed a more progressive, continuous rise reaching a maximum activity plateau after

90 minutes. Several factors render the comparison between our results and data found in the literature difficult, due to the differing characteristics of our T98G cells and other experimental cell lines. In particular, the accumulation kinetics of ^{18}F -FET in T98G cells is quite different from that described in the 9L cancer cell line, where a wash-out is observable after 60 min of incubation.³¹ This phenomenon is less evident in F98 cell culture, with an initially fast uptake, peaking at 10 min, and followed by a nearly constant or slow wash-out rate during the incubation period of 60 min.³² On the other hand, Habermeier *et al.* described a progressive accumulation of non-radioactive FET in a NL229 human glioblastoma line up to 4 hours.³³

Both Hebermaier *et al.*³³ and Heiss *et al.*³⁴ tested the release of FET. Heiss *et al.*³⁴ demonstrated a quick efflux of ^{18}F -FET from porcine SW707 colon cancer cells, only 7% of the original activity remained in the experimental cells after 6 min incubation time, when the culture medium was replaced with a new tracer-free medium. Different results were reported by Habermeier *et al.*³³ demonstrating that, although ^{18}F -FET is not incorporated into proteins, an intracellular metabolism could lead to another impermeable derivative trapped within the glioma cells. This would suggest an asymmetry of intra- and extracellular recognition by LAT1. The ^{18}F -FCH kinetic pattern in our study was quite similar to that seen in 9L glioma cells³⁵, both in the normoxic or hypoxic conditions, reaching maximum activity at 120 minutes. Bansal *et al.*³⁵ reported a negligible washout of ^{18}F -FCH of about 13% after 2 hours in the release experiments because this radiopharmaceutical remains trapped in the cells as phospho-FCH. This demonstrates the slow rate of dephosphorylation. Conversely, apparent discrepancies between our in vitro observations and the in vivo glioma rat model emerged, both in terms of relative uptake and tracer kinetics. These mismatches could be explained by different causes, including radiotracer accumulation detected by the external imaging device or direct measurement of the pathological specimen, which provides information not only of the true tumour uptake but also of the inflammatory cells. In this setting, ^{18}F -FET accumulates predominantly in the tumour rather than in inflammatory cells, differing from ^{11}C -MET and suggesting that different subtypes of the L system are involved.³⁶ Contrarily, ^{18}F -FCH accumulation has been demonstrated in brain radiation injuries and in murine atherosclerotic plaques - probably mediated by macrophages - as well as in a turpentine-induced sterile abscess.^{37,38} In a rat

model of acute brain injury (cryolesion and proton-induced necrosis) ^{18}F -FET uptake was mainly due to the disruption of the blood-brain-barrier while ^{18}F -FCH was additionally taken up by inflammatory cells.³⁹ Similarly, a comparison of ^{18}F -FCH and ^{18}F -FET in a rat glioma radionecrosis indicated ^{18}F -FET as the superior discriminant between viable tumour and inflammatory changes³⁰, although evidence of increased ^{18}F -FET uptake in perilesional reactive astrogliosis after radiotherapy could lead to an overestimation of tumor size.⁴⁰

Conclusions

The in vitro model used in these experiments allows direct comparison of different radiopharmaceuticals as potential candidates for neuro-oncological PET imaging. The results obtained indicate a superiority of ^{18}F -FCH in terms of absolute uptake and in obtaining an optimal target to non-target ratio in the brain, whereas the major limitation of ^{18}F -FDG is its physiological parenchymal uptake. However, a direct translation to clinical application is hampered by certain conflicting results reported in the literature. ^{18}F -FET could be more useful in the presence of reparative changes after therapy, where the higher affinity of ^{18}F -FCH to inflammatory cells makes it more difficult to discriminate between tumour persistence and non-neoplastic changes. Additional studies on the influence of inflammatory tissue and radionecrotic cellular components on radiopharmaceutical uptake will be necessary to elucidate these topics.

References

1. Purves D, Augustine GJ, Fitzpatrick D, Katz LC, LaMantia AS, McNamara JO, et al. *Neuroscience (2nd edition)*. Sunderland (MA): Sinauer Associates; 2001.
2. Park JK, Hodges T, Arko L, Shen M, Dello Iacono D, McNabb A, et al. Scale to predict survival after surgery for recurrent glioblastoma multiforme. *J Clin Oncol* 2010; **28**: 3838-43.
3. Chaichana KL, McGirt MJ, Latterra J, Olivi A, Quiñones-Hinojosa A. Recurrence and malignant degeneration after resection of adult hemispheric low-grade gliomas. *J Neurosurg* 2010; **112**: 10-7.
4. Wick W, Stupp R, Beule AC, Bromberg J, Wick A, Ernemann U, et al. A novel tool to analyze MRI recurrence patterns in glioblastoma. *Neuro Oncol* 2008; **10**: 1019-24.
5. Barajas RF Jr, Chang JS, Segal MR, Parsa AT, McDermott MW, Berger MS, et al. Differentiation of recurrent glioblastoma multiforme from radiation necrosis after external beam radiation therapy with dynamic susceptibility-weighted contrast-enhanced perfusion MR imaging. *Radiology* 2009; **253**: 486-96.
6. Fatterpekar GM, Galheigo D, Narayana A, Johnson G, Knopp E. Treatment-related change versus tumor recurrence in high-grade gliomas: a diagnostic conundrum—use of dynamic susceptibility contrast-enhanced (DSC) perfusion MRI. *AJR Am J Roentgenol* 2012; **198**: 19-26.

7. Patronas NJ, Di Chiro G, Brooks RA, DeLaPaz RL, Kornblith PL, Smith BH, et al. Work in progress: [18F] fluorodeoxyglucose and positron emission tomography in the evaluation of radiation necrosis of the brain. *Radiology* 1982; **144**: 885-9.
8. Di Chiro G, Oldfield E, Wright DC, De Michele D, Katz DA, Patronas NJ, et al. Cerebral necrosis after radiotherapy and/or intraarterial chemotherapy for brain tumors: PET and neuropathologic studies. *AJR Am J Roentgenol* 1988; **150**: 189-97.
9. Wong TZ, van der Westhuizen GJ, Coleman RE. Positron emission tomography imaging of brain tumors. *Neuroimaging Clin N Am* 2002; **12**: 615-26.
10. Olivero WC, Dulebohn SC, Lister JR. The use of PET in evaluating patients with primary brain tumors: Is it useful? *J Neurol Neurosurg Psychiatry* 1995; **58**: 250-2.
11. Ramirez de Molina A, Rodriguez-Gonzalez A, Gutierrez R, Martinez-Pineiro L, Sanchez J, Bonilla F. Overexpression of choline kinase is a frequent feature in human tumor derived cell lines and in lung, prostate, and colorectal human cancers. *Biochem Biophys Res Commun* 2000; **296**: 580-3.
12. Shinoura N, Nishijima M, Hara T, Haisa T, Yamamoto H, Fujii K. Brain tumors: detection with C-11 choline PET. *Radiology* 1997; **202**: 497-503.
13. Sollini M, Sghedoni R, Erba PA, Cavuto S, Froio A, De Berti G, et al. Diagnostic performances of [18F]fluorocholine positron emission tomography in brain tumors. *Q J Nucl Med Mol Imaging* 2015; Sep 1 [Epub ahead of print]; PMID: 26329494.
14. Friedland RP, Mathis CA, Budinger TF. Labelled choline and phosphorycholine: Body distribution and brain autoradiography. *J Nucl Med* 1983; **24**: 812-5.
15. Wyss MT, Weber B, Honer M, Späth N, Ametamey SM, Westera G, et al. ¹⁸F-choline in experimental soft tissue infection assessed with autoradiography and high-resolution PET. *Eur J Nucl Med Mol Imaging* 2004; **3**: 312-6.
16. Oxender DL, Christensen HN. Distinct mediating systems for the transport of neutral amino acids by the Ehrlich cell. *J Biol Chem* 1963; **238**: 3686-99.
17. Kaim AH, Weber B, Kurrer MO, Westera G, Schweitzer A, Gottschalk J, et al. ¹⁸F-FDG and ¹⁸F-FET uptake in experimental soft tissue infection. *Eur J Nucl Med Mol Imaging* 2002; **29**: 648-54.
18. Buck D, Förschler A, Lapa C, Schuster T, Vollmar P, Korn T, et al. ¹⁸F-FDG PET detects inflammatory infiltrates in spinal cord experimental autoimmune encephalomyelitis lesions. *J Nucl Med* 2012; **53**: 1269-76.
19. Messing-Jünger AM, Floeth FW, Pauleit D, Reifenberger G, Willing R, Gärtner J, et al. Multimodal target point assessment for stereo-tactic biopsy in children with diffuse bithalamic astrocytomas. *Child's Nerv Syst* 2002; **18**: 445-9.
20. Pauleit D, Floeth F, Tellmann L, Hamacher K, Hautzel H, Müller HW, et al. Comparison of O-(2-[18F]-fluoroethyl)-L-tyrosine PET and 3-123I-iodo-alpha-methyl-L-tyrosine SPECT in brain tumors. *J Nucl Med* 2004; **45**: 374-81.
21. Pöpperl G, Goldbrunner R, Gildehaus FJ, Kreth FW, Tanner P, Holtmannspötter M, et al. O-(2-[18F]-fluoroethyl)-L-tyrosine PET for monitoring the effects of convection-enhanced delivery of paclitaxel in patients with recurrent glioblastoma. *Eur J Nucl Med Mol Imaging* 2005; **32**: 1018-25.
22. Pöpperl G, Götz C, Rachinger W, Schnell O, Gildehaus FJ, Tonn JC, et al. Serial O-(2-[18F]-fluoroethyl)-L-tyrosine PET for monitoring the effects of intracavitary radioimmunotherapy in patients with malignant glioma. *Eur J Nucl Med Mol Imaging* 2006; **33**: 792-800.
23. Piroth MD, Pinkawa M, Holy R, Klotz J, Nussen S, Stoffels G, et al. Prognostic value of early [18F]fluoroethyltyrosine positron emission tomography after radiochemotherapy in glioblastoma multiforme. *Int J Radiat Oncol Biol Phys* 2011; **30**: 176-84.
24. Wyss M, Hofer S, Bruehlmeier M, Hefti M, Uhlmann C, Bärtschi E, et al. Early metabolic responses in temozolomide treated low-grade glioma patients. *J Neurooncol* 2009; **95**: 87-93.
25. Yao KC, Komata T, Kondo Y, Kanzawa T, Kondo S, Germano IM. Molecular response of human glioblastoma multiforme cells to ionizing radiation: cell cycle arrest, modulation of the expression of cyclin-dependent kinase inhibitors, and autophagy. *J Neurosurg* 2003; **98**: 378-84.
26. Stein GH. T98G: an anchorage-independent human tumor cell line that exhibits stationary phase G1 arrest in vitro. *J Cell Physiol* 1979; **99**: 43-54.
27. Buroni FE, Pasi F, Persico MG, Lodola L, Aprile C, Nano R. Evidence of ¹⁸F-FCH uptake in human T98G glioblastoma cell line. *Anticancer Res* 2015; **35**: 6443-8.
28. Wyss MT, Spaeth N, Biollaz G, Pahnke J, Alessi P, Trachsel E, Treyer V, et al. Uptake of ¹⁸F-Fluorocholine, ¹⁸F-FET, and ¹⁸F-FDG in C6 gliomas and correlation with 131I-SIP(L19), a marker of angiogenesis. *J Nucl Med* 2007; **48**: 608-14.
29. Spaeth N, Wyss MT, Pahnke J, Biollaz G, Lutz A, Goepfert K, et al. Uptake of ¹⁸F-fluorocholine, ¹⁸F-fluoro-ethyl-L-tyrosine and ¹⁸F-fluoro-2-deoxyglucose in F98 gliomas in the rat. *Eur J Nucl Med Mol Imaging* 2006; **33**: 673-82.
30. Bolcaen J, Descamps B, Deblaere K, Boterberg T, De Vos Pharm F, Kalala JP, et al. (18F)F-fluoromethylcholine (FCho), (18F)F-fluoroethyltyrosine (FET), and (18F)F-fluorodeoxyglucose (FDG) for the discrimination between high-grade glioma and radiation necrosis in rats: a PET study. *Nucl Med Biol* 2015; **42**: 38-45.
31. Wang L, Lieberman BP, Ploessl K, Kung HF. Synthesis and evaluation of ¹⁸F labelled FET prodrugs for tumor imaging. *Nucl Med Biol* 2014; **41**: 58-67.
32. Wang HE, Wu SY, Chang CW, Liu RS, Hwang LC, Lee TW, et al. Evaluation of F-18-labeled amino acid derivatives and [18F]FDG as PET probes in a brain tumor-bearing animal model. *Nucl Med Biol* 2005; **32**: 367-75.
33. Habermeyer A, Graf J, Sandhöfer BF, Boissel JP, Roesch F, Closs EI. System L amino acid transporter LAT1 accumulates O-(2-fluoroethyl)-L-tyrosine (FET). *Amino Acids* 2015; **47**: 335-44.
34. Heiss P, Mayer S, Herz M, Wester HJ, Schwaiger M, Senekowitsch-Schmidtker R. Investigation of transport mechanism and uptake kinetics of O-(2-[18F] fluoroethyl)-L-tyrosine in vitro and in vivo. *J Nucl Med* 1999; **40**: 1367-73.
35. Bansal A, Shuyan W, Hara T, Harris RA, Degrado TR. Biodisposition and metabolism of [(18F)]fluorocholine in 9L glioma cells and 9L glioma-bearing fisher rats. *Eur J Nucl Med Mol Imaging* 2008; **35**: 1192-203.
36. Stöber B, Tanase U, Herz M, Seidl C, Schwaiger M, Senekowitsch-Schmidtker R. Differentiation of tumour and inflammation: characterisation of [methyl-3H]methionine (MET) and O-(2-[18F]fluoroethyl)-L-tyrosine (FET) uptake in human tumour and inflammatory cells. *Eur J Nucl Med Mol Imaging* 2006; **33**: 932-9.
37. van Waarde A, Elsinga PH. Proliferation markers for the differential diagnosis of tumor and inflammation. *Curr Pharm Des.* 2008; **14**: 3326-39.
38. Langen KJ, Hamacher K, Weckesser M, Floeth F, Stoffels G, Bauer D, et al. O-(2-[18F]fluoroethyl)-L-tyrosine: uptake mechanisms and clinical applications. *Nucl Med Biol* 2006; **33**: 287-94.
39. Spaeth N, Wyss MT, Weber B, Scheidegger S, Lutz A, Verwey J, et al. Uptake of ¹⁸F-fluorocholine, ¹⁸F-fluoroethyl-L-tyrosine, and ¹⁸F-FDG in acute cerebral radiation injury in the rat: implications for separation of radiation necrosis from tumor recurrence. *J Nucl Med* 2004; **45**: 1931-8.
40. Piroth MD, Prasath J, Willuweit A, Stoffels G, Sellhaus B, van Oosterhout A, et al. Uptake of O-(2-[18F]fluoroethyl)-L-tyrosine in reactive astrocytosis in the vicinity of cerebral gliomas. *Nucl Med Biol* 2013; **40**: 795-800.