

Advances in the management of craniopharyngioma in children and adults

Mojca Jensterle^{1,2}, Soncka Jazbinsek^{2,3}, Roman Bosnjak^{2,4}, Mara Popovic^{2,5}, Lorna Zadavec Zaletel^{2,6}, Tina Vipotnik Vesnaver^{2,7}, Barbara Faganel Kotnik^{2,8}, Primoz Kotnik^{2,3}

¹ Department of Endocrinology, Diabetes and Metabolism, University Medical Centre Ljubljana, Ljubljana, Slovenia

² Medical Faculty, University of Ljubljana, Ljubljana, Slovenia

³ Department of Endocrinology, Diabetes and Metabolism, University Children's Hospital, University Medical Centre Ljubljana, Ljubljana, Slovenia

⁴ Department of Neurosurgery, University Medical Centre Ljubljana, Ljubljana, Slovenia

⁵ Institute of Pathology, Medical Faculty, University of Ljubljana, Ljubljana, Slovenia

⁶ Department of Radiotherapy, Institute of Oncology Ljubljana, Ljubljana, Slovenia

⁷ Clinical Institute of Radiology, University Medical Centre Ljubljana, Ljubljana, Slovenia

⁸ Department of Hematology and Oncology, University Children's Hospital, University Medical Centre Ljubljana, Ljubljana, Slovenia

Radiol Oncol 2019; 53(4): 388-396.

Received 21 June 2019

Accepted 11 July 2019

Correspondence to: Asst. Prof. Primoz Kotnik, M.D., Ph.D., Department of Endocrinology, Diabetes and Metabolism, University Children's Hospital, University Medical Center Ljubljana, Bohoričeva 20, SI-1000 Ljubljana, Slovenia. Department of Pediatrics, Faculty of Medicine, University of Ljubljana, Bohoričeva 20, SI-1000 Ljubljana, Slovenia. E-mail: primoz.kotnik@mf.uni-lj.si

Disclosure: No potential conflicts of interest were disclosed.

Background. Childhood and adult-onset craniopharyngioma is a rare embryogenic tumor of the sellar, suprasellar, and parasellar region. Survival rates are high; however, tumor location and treatment sequelae including endocrine deficits, visual impairment, metabolic complications, cognitive and psychosocial deficits can significantly impair patient's quality of life. There is considerable controversy regarding the optimal management of craniopharyngiomas. Subtotal resection of the tumor followed by targeted irradiation to avoid further hypothalamic damage is currently indicated. Novel insights in the tumor's molecular pathology present the possibility for targeted therapy possibly decreasing the rate and severity of treatment-associated morbidity.

Conclusions. Craniopharyngioma should be seen as a chronic disease. To achieve optimal outcomes a multidisciplinary team of specialized neurosurgeons, neuro-radiologists, neuro-oncologists, pathologists and endocrinologists should be involved in the diagnosis, planning of the surgery, irradiation and long-term follow-up.

Key words: craniopharyngioma; hypopituitarism; metabolic syndrome; proton beam therapy; *CTNIB1* gene; MAPK/ERK pathway

Introduction

Craniopharyngioma (CP) is a rare epithelial tumor of the sellar and parasellar region, histologically of low-grade (WHO grade I). They represent approximately 1% of all primary intracranial neoplasms in adults and 1.2–4% in children, making them the most common sellar tumors in the latter. The overall incidence of CP is 1.24–1.46 per million/year with no difference between gender and race.¹⁻⁵

In 1904, Austrian pathologist Jakob Erdheim first reported that CP arises from squamous cell rests occurring in the region of the remnant hypophyseal/pharyngeal duct, most frequently originating around the infundibulum. Rarely CP arises in less typical locations along the remnants of the primitive craniopharyngeal duct including the nasopharynx, sphenoid bone, or as primary intraventricular lesions.^{6,7}

The growth of CP is slow, but their location enables them to be large at the time of diagnosis, extending supero-posteriorly into the third ventricle and hypothalamus, compressing supero-anteriorly the optic pathways and inferiorly the pituitary gland, impairing their functions. Adherence to these critical structures often limits the ability of the surgeon to completely resect the lesion, exposing patients to a high risk of recurrence. The overall 5-year survival rate is high (ranging from 91–98%). Unfortunately, the morbidity rate is equally high with severe neuroendocrine sequelae, impaired social and physical functionality and a negative impact on quality of life (QoL) in all patients. Because of this, strict follow up by a specialized multidisciplinary team is paramount.⁸⁻¹³

High morbidity rates following aggressive complete surgical removal were reported, therefore a change in the paradigm towards a subtotal removal of the tumor mass has now been proposed. As CP is known to recur frequently, postoperative irradiation has become a part of the standard treatment.¹⁴⁻¹⁶ The first reports after the introduction of proton beam therapy show a decrease in adjuvant therapy induced morbidity, but long-term follow up data is still needed to evaluate its role in CP treatment.¹⁷

Despite all these recent improvements, we still observe high morbidity rates, especially panhypopituitarism, visual and neurological deficits, hypothalamic obesity (HO), increased cardiovascular issues and reduced quality of life, inciting the demand for alternative therapies to surgery.^{8,18-22} Novel insights into the molecular pathogenesis of adamantinomatous craniopharyngioma (ACP) and papillary craniopharyngioma (PCP) have offered the possibility of pharmaceutical therapy targeting pathogenic pathways, which could decrease the chance of recurrence and possibly the initial tumor size.^{23,24}

The aim of the present review is to accumulate up-to-date data to help in the development of national guidelines for the management of subjects with CP and the national registry of these patients. The review is presented on behalf of the national multidisciplinary craniopharyngioma working group.

Clinical presentation

Initial symptoms of CP are frequently unspecific, and the diagnosis can be made relatively late. According to the data from HIT Endo and

Craniopharyngioma 2000 study data the most frequent symptoms before the diagnosis in children are headache (68%), followed by visual impairment (55%), growth failure (36%), nausea (34%) neurologic deficits (23%), polydipsia/polyuria (19%) and weight gain (16%).²⁵ In adults, the most common presenting symptoms are visual impairment (40–84%), headache (56%), menstrual irregularities in women (57%), loss of energy (32–48%) nausea and vomiting (26%), lethargy (26%), and weight gain (13–15%).^{13,26,27} The period from initial symptoms to the diagnosis does not correlate with tumor size, hypothalamic involvement, functional capacity or survival.²⁶ It is however emphasized that weight gain and growth retardation are early signs of CP in children that should lead the investigator to further diagnostic workup. Raised intracranial pressure and/or acute vision loss because of tumor obstructing CSF pathways leading to obstructive hydrocephalus can also be the first manifestation, according to Mortini *et al.* more often identified in children.²⁶ In these patients, urgent surgical decompression is required and their presenting symptoms are the only ones connected with lower 10-year overall survival.²⁵

Imaging and treatment

There is evidence that adequate presurgical imaging and assessment of hypothalamic involvement of CP is extremely important in estimating prognosis and long-term quality of life. Initial tumor involvement of the third ventricular floor, mammillary bodies and/or posterior hypothalamus on imaging are associated with a worse long-term prognosis due to hypothalamic obesity, regardless of chosen treatment strategies.²⁸⁻³² Magnetic resonance imaging (MRI) is the standard imaging modality in CP, but reliable discrimination between ACP and PCP based on neuroradiological criteria is not possible.³³ In addition, computer tomography (CT) limited to the sellar area and excluding orbital areas for better determinations of calcifications within the tumor is recommended. Papillary CP namely lacks calcifications and can be misdiagnosed as another type of a suprasellar tumor (Figure 1).³⁴

A preoperative radiological grading system has been developed for pediatric patients.³⁵ Using this grading, the treatment of choice for CP without hypothalamic involvement (HI) (type 0 – no HI on MRI scan and type 1 – distorts or elevates the hypothalamus) is an attempt of complete resection

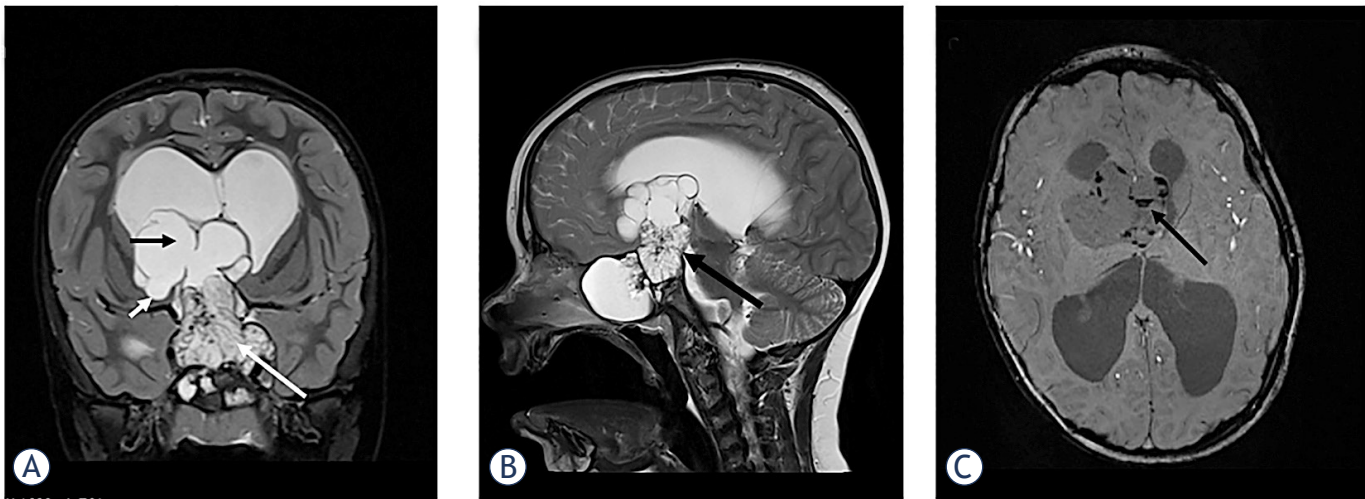


FIGURE 1. Large, partially solid, partially multicystic adamantinomatous craniopharyngioma in a 5-year old boy. **(A)** Coronal T2 sequence through sellar region; solid part of the tumor (white arrow) involves enlarged sella turcica, parasellar regions, occupies the suprasellar cistern and the third ventricle. The cystic portion of the tumor (black arrow) extends into the lateral ventricles and on the right side it infiltrates the adjacent brain parenchyma (small arrow). Lateral ventricles are enlarged with a band of periventricular transependymal edema as a sign of acute hydrocephalus. **(B)** Sagittal T2 sequence through the sellar region; Hypothalamus and mammillary bodies are not visible (arrow). **(C)** SWI sequence through the multicystic portion of the tumor shows multiple calcifications in the cyst walls (arrow).

(gross total resection - GTR), with preservation of visual, pituitary and hypothalamic function. For tumors located unfavourably (type 2 – hypothalamus not visible on MRI scan) GTR is not recommended. For prevention of severe morbidity, a subtotal resection (STR) should be performed, followed by adjuvant therapy.^{28,35,36}

The optimal therapeutic strategy for CP is however still controversial. Surgical treatment of these lesions remains among the most challenging for neurosurgeons because of their complex and highly variable topographical relationships with crucial neural and vascular structures such as the optic chiasm, hypothalamus, third ventricle, and vessels of the circle of Willis. So far, no single best treatment paradigm exists, and the extent of surgical resection or adjuvant therapy should be considered on a case-to-case basis.

Previous studies show that the most significant factor associated with recurrence is the extent of surgical resection regardless of the histological subtype, but attempts of GTR in patients with tumor invading the hypothalamus results in significant morbidity in terms of hypothalamic dysfunction.^{16,37,38} Therefore, the treatment focus is on prevention of additional hypothalamic injury. Precise presurgical imaging for defining the type based on location (primary third ventricle CP or primary suprasellar CP) and topography is essential.^{30,32} Functional MRI of the infundibulum, tuber

cinereum, mammillary bodies, and hypothalamus, although not currently feasible, may be helpful in distinguishing precise topography of CPs and planning the surgical approach.³⁹

No significant difference was observed in 5- and 10-year overall survival (OS) and progression-free survival between GTR and STR followed by adjuvant therapy. STR without adjuvant therapy is associated with worse OS than STR with adjuvant therapy, with unacceptably high recurrent rates up to 63%.^{15,40,41}

In patients that underwent STR postoperative external beam radiotherapy (RT) is presently standard of care to achieve an optimal progression-free survival.^{13,41-44} In most studies, attention has been paid to radiation fibrosis syndrome while the impact of RT on QoL has been studied to a much lesser extent. Kiehna and Merchant reported results of meta-analysis of studies on pediatric CPs. They found out that more than two-thirds of patients treated with surgery and radiation therapy in childhood have favorable outcomes, and this rate is even higher in the modern era.⁴³ The most recent advances in the treatment of craniopharyngioma have focused on minimizing treatment-related toxicity. These advances include endoscopic surgery and precision radiotherapy. In the last decades radiation therapy technology has improved dose conformity and provided decreased doses to adjacent critical structures (hypothalamus, optic tract, pituitary gland, carotid

arteries, medial temporal lobe structures, etc.) with the goal of reducing long-term sequelae, especially endocrinologic and visual ones. Conformal RT enables a better coverage of the tumor while preserving surrounding tissue therefore decreasing the risk of adverse effects. Current techniques include fractionated three-dimension conformal RT, intensity modulated radiotherapy (IMRT), fractionated stereotactic radiotherapy (FSRT) or recently proton beam therapy (PBT). Tumor control between 80 and in excess of 90% can be achieved.⁴⁵ Greenfield *et al.* published the first work on the use of IMRT in children with CPs and found this technique promising.⁴⁶ Harrabi *et al.* with colleagues reported that FSRT leads to excellent results in patients with CP regarding local control, overall survival and preservation of organ function.⁴⁷ Lately, in order to lessen adverse effects of radiation, PBT is increasingly used for the treatment of CPs in children. The major advantage of proton therapy is the high degree of dose conformity to the target. Beltran *et al.* retrospectively evaluated proton treatment plans with IMRT plan. He concluded that compared with photon IMRT proton therapy has the potential to significantly reduce whole brain and body irradiation. Result of that is lower collateral damage to critical structures thus reducing the risk of complications and secondary cancers.⁴⁸

Regine and Kramer reported that a total dose of > 54 Gy is recommended for external radiation using conventional techniques with excessively rising recurrence rates for doses < 54 Gy. However, limitations are posed by the tolerance doses of vital organs in the vicinity. Therefore, commonly doses between 50–55.8 Gy, delivered in 1.5- to 2.0 Gy fractions, 5 days per week for a period of 6 weeks are used.^{45,49}

If a cystic component in a tumor is present, careful monitoring during radiotherapy is necessary. Namely, dynamic cyst changes can occur throughout the 6 weeks of RT, recommending weekly MRIs during treatment to identify these changes, and to adapt RT plan according to changes in tumor volume.^{13,46,50}

Stereotactic radiosurgery is an alternative to fractionated treatments in patients with craniopharyngioma harboring smaller lesions, but caution is needed because high dose applied in single fraction can carry higher risk for damage of vital structures.^{45,51}

With the future development of targeted therapy, we should strive towards more personalized risk-adapted treatment strategy, taking the histological type of tumor and its mutations into consideration.

Molecular pathology

There are two main histological CP subtypes – adamantinomatous craniopharyngioma (ACP) and papillary craniopharyngioma (PCP). ACPs are more common and can be diagnosed at any age but are predominantly observed in the pediatric population. The average age of diagnosis of this subtype shows an asymmetric bimodal distribution, with a larger peak at 5–14 years and a smaller at 50–74 years.¹ PCPs account for approximately 11–14% of CPs and mainly occur in adults. The average age of diagnosis for this subtype is 44 ± 15 years.²⁷ PCPs have higher 5-year survival rates and less aggressive disease progression. PCPs are solid, more well circumscribed, while ACPs adhere to the surrounding, consist of a mixture of cysts and nodules and changes like fibrosis, calcifications and hemorrhages are seen.^{52,53}

Important advances were made lately regarding the determination of the genes involved in the pathogenesis of the tumor that could have an important effect on the treatment modalities. ACPs are mainly caused by activating mutations of the Wingless pathway (WNT pathway) gene *CTNNB1*, encoding the β -catenin. Activating mutations in the gene are determined in more than two-thirds of CPs in recent studies.⁵⁴ They increase the resistance of β -catenin to proteasomal degradation resulting in its intranuclear accumulation. These clusters are pathologically unique for human ACP and are not present in any other pituitary tumour.^{55,56} In one third of ACP the *CTNNB1* mutation is not identified, suggesting other genetic/epigenetic events might also be the cause of WNT activation.⁵⁴ Recently involvement of MAPK/ERK pathway in the tumorigenesis of ACP has been determined, which opens novel therapeutic opportunities by suppression of this pathway with chemical agents as is MEK inhibitor trametinib.⁵⁷

In PCP subgroup *BRAF* V600E mutations were detected in about 90% and appear to be the critical event in the pathogenesis.^{54,56} The same mutation is present in 7% of human cancers.⁵⁸ *BRAF* is a proto-oncogene encoding serine-threonine kinase and is involved in growth factor signaling and regulation. Its mutation results in a constitutively active form promoting cell proliferation and tumor growth. Although rarely, a coexistence of both mutations may occur.⁵⁹ Previous studies did not show larger chromosomal aberrations in any type of CP.⁶⁰

While agents that target WNT signaling remain in development, the availability of *BRAF* inhibitors such as vemurafenib and dabrafenib suggests that

patients with papillary craniopharyngiomas could immediately benefit from such targeted therapeutics.^{23,24,61-63} Vemurafenib and dabrafenib are already used as targeted therapy in other types of tumors with the same mutation. One of the most recent studies with the longest follow-up period, Himes BT *et al.*, demonstrated reduction of the tumor size using dabrafenib as a monotherapy for the treatment of recurrence of PCP. Patients remained symptom-free 1 year after administration and there was no radiographic evidence of tumor progression.²⁴ Recently a successful combination therapy with a dabrafenib and trametinib in reducing PCP in a subject with *BRAF* V600E mutation was published.²³

Prieto and Pascual published a comprehensive overview about tissue biomarkers being currently used as predictors of tumour recurrence and aggressiveness of their behaviour, stressing that their precise impact still needs to be closely evaluated in conjunction with the degree of tumor removal, the tumor topography, the pattern of tumor attachment, and the histological variant observed in each case. Their early identification could also improve patient outcome, but so far tumor remnant after initial surgery remains the only well-established factor for recurrence.⁵⁴

Long term consequences and prognosis

The long-term morbidity of craniopharyngiomas is associated with damage to critical neuronal structures by the primary or recurrent tumor combined with the adverse effects of the therapeutic interventions. Despite the improvements in the last decades, the outcome is still rather unfavorable. Patients with childhood-onset CP experience significantly more panhypopituitarism, morbid obesity, epilepsy and psychiatric conditions in comparison to patients with adult-onset disease.^{8,11,14,19,64} Long term outcomes were shown to be particularly worse in the case of hypothalamic involvement, reducing 20-year OS rate and quality of life of these patients.^{9,10,25} In this section, we will try to focus on differences in sequela between adult and childhood population.

Endocrine consequences

Hypothalamo-pituitary hormone deficiencies are determined in 40–87% of children at the time of childhood-onset CP and 73% adults present with

at least one deficient hypothalamic-pituitary axis.^{8,13,21,35,65,66} As shown in Table 1, after initial treatment the prevalence of endocrine deficits ranging from single hormone insufficiency to panhypopituitarism increases and it is seen in almost all patients, requiring lifelong follow-up by an endocrinologist.

In children with CP growth hormone deficiency is most frequently seen, occurring in up to 96%, adrenocorticotrophic (ACTH), gonadotropin, thyroid stimulating hormone (TSH) deficiency follow in decreasing order. Central diabetes insipidus resulting from anti-diuretic hormone (ADH) deficiency occurs almost twice more frequently in children than in adults, can be transient after the procedure and it persists in 65–96% of childhood-onset CP subjects.^{8,18,21} Substitution therapy with hr-GH is safe, effective and does not affect relapse and progression rates.⁶⁷ In patients with GH substitution, a better QoL has been reported.¹¹ In children after the surgery, despite their GH deficiency, a normal or accelerated growth pattern has been observed. Activation of IGF-1 by hypothalamic hyperphagia/obesity induced hyperinsulinism is suggested to explain this growth pattern.⁶⁸

Sixty-one % of adults have panhypopituitarism after treatment for CP, most commonly affecting gonadotropin axis.⁸ Post-surgical onset of central diabetes insipidus was observed in up to 69.6% of the patients.³³ Adequate timing and dosing of glucocorticoids, thyroxine, sex steroid and ADH is essential. Concerning GH substitution, observational studies suggest that GH replacement in adult-onset CP does not increase the risk of tumor recurrence. Lifelong surveillance by an endocrinologist is required.³³

Metabolic consequences

Damage of the posterior hypothalamic region results in hypothalamic obesity (HO), which occurs in 40–66% of patients with childhood-onset CP and has a major impact on the outcome.⁹ Especially preoperative lesions that include the dorsal hypothalamic area and dorsomedial nucleus in the posterior hypothalamus are at very high risk for rapid and pathological weight gain during the first year following surgery, sometimes beginning in the months prior to surgery. Postsurgical diabetes insipidus was found to be an endocrine marker for the development of HO.²⁹

The major mechanisms that reinforce HO are vagally mediated hyperinsulinemia, disrupted

TABLE 1. Comparison of pediatric and adult-onset craniopharyngioma characteristics

	Pediatric-onset	Adult-onset
Age at presentation	30–50 % of all CPs Peak at 5–14 years ¹	Peak at 40–44 years ²
Gender distribution (m/f)	Equal ^{8,21}	Equal ^{8,27}
Most frequent presentation	Headache (68–85%) Visual impairment (36–55%) Growth failure (7–36%) ^{9,35,66}	Visual impairment (40–84%) Menstrual irregularities (57%) Headache (42–56%) ^{13,26,27}
Pathohistological type	Adamantinomatous 99% Papillary extremely rare*	Papillary 14–50% ³³
Initial hypothalamic involvement	42–66% ^{8,9,35}	42% ¹⁸
Endocrine deficits at diagnosis		
Any	40–87% ^{8,13,21,35,65,66}	41–73% ⁸
GH	41–75% ^{8,13,21,35,65,66}	18–86% ^{8,13}
FSH/LH	20–56% ^{8,13,21,35,65,66}	29–74% ^{8,13}
ACTH	8–68% ^{8,13,21,35,65,66}	35–58% ^{8,13}
TSH	15–32% ^{8,13,21,35,65,66}	35–56% ^{8,13}
ADH	7–17% ^{8,13,21,35,65,66}	6–17% ^{8,13}
Pituitary hormone deficiencies after treatment		
Any	64–100% ^{8,64}	48–97% ^{8,64}
GH	93–96% ^{8,18,21}	52–68% ^{8,18}
FSH/LH	59–95% ^{8,18,21}	70–94% ^{8,18}
ACTH	78–100% ^{8,18,21}	74–88% ^{8,18}
TSH	86–100% ^{8,18,21}	81–92% ^{8,18}
ADH	65–96% ^{8,18,21}	43–70% ^{8,18}
Panhypopituitarism***	43–100% ^{8,18,64}	59–74% ^{8,18,64}
Obesity**	44–64% ^{8,9,19,64}	41–47% ^{8,19,64}

* Only 23 identified cases since 1995.⁸³

** Obesity was defined with BMI > 30 kg/m² in adults and BMI >95. percentile for their age in children.

*** Panhypopituitarism was defined as present when 3 anterior pituitary deficiencies were diagnosed in one patient (growth hormone deficiency, thyroid-stimulating hormone deficiency, adrenocorticotropic hormone deficiency, and late puberty in children or hypogonadism in adults).

ACTH = adrenocorticotropic hormone; ADH = vasopressin (antidiuretic hormone); FSH/LH = follicle stimulating hormone/luteinizing hormone; GH = growth hormone; TSH = thyroid stimulating hormone

or impaired sensitivity to feeding-related signals for leptin, insulin, and ghrelin, altered energy expenditure, reduced melatonin levels, increased daytime sleepiness and reduced physical activity. CNS stimulating agents, somatostatin analogs, a supraphysiological dosage of thyroid hormone, GLP-1 RAs in patients with intact hypothalamus and hindbrain and bariatric surgery have been considered as a potential treatment strategy in adult population based on some individual-level experiences or serial case reports.⁶⁹ Early involvement of a dietician, psychologist and physiotherapist by providing individual lifestyle and dietary advice may decrease aggravation of HO. Regular visits to the outpatient clinic should be offered to

closely monitor weight development and to support patients. Unfortunately, no treatment options for HO have been proven to be effective so far.⁶⁹

In 178 patients with CP Wijnen *et al.* reported the prevalence of metabolic syndrome (MetS) in almost half of the patients with HI (48% with childhood onset and 45% with adult-onset CP). Obesity and reduced HDL cholesterol were more prevalent in childhood-onset patients, whereas hypertension and elevated triglycerides were more prevalent in adults. MetS, regardless of the age of onset, was more frequent in female patients than in male patients (54% vs 40%) and in patients not treated for their GH deficiency (57% vs. 43%).¹⁹ Non-alcoholic fatty liver disease occurs in about 50% of childhood-

onset CP patients with HI, especially in patients treated with stimulants for their daytime sleepiness and severe fatigue.^{70,71} Increased mortality due to cardiovascular disease in hypopituitarism is already known and it is 3 to 19-fold higher in this specific subgroup of patients with CP. In women with CP, an even higher risk is reported.^{10,72-75}

Visual impairment

Defoort *et al.* reported the presence of visual disturbances in up to 96% of patients at the diagnosis in pediatric CP cohort of twenty-nine patients. Typical manifestations are the loss of visual acuity, visual field defects, strabismus, papilledema or optic nerve atrophy. In children, the loss of visual acuity was most frequently observed, with post-surgical improvement in 46-66%.⁷⁶ The risk of post-surgical visual impairment increases with the initial pre-surgical severe visual defect and localization of the tumor in pre-chiasmatic area.⁶⁶ Wijnen *et al.* reports visual acuity disorder and visual field defect 63-66% of pediatric and adult patients after surgery.⁸

Cognitive and psychosocial deficits

Memory, attention, impulse control, motivation and socialization deficits are present in CP patients.^{77,78} They cannot be fully explained by a lesion in the hypothalamus alone.

In patients with childhood-onset CP, the most consistent findings in the cognitive domain are impairments in learning and episodic memory. There is also evidence that hypothalamic tumor involvement reduces gray and white matter volumes in fronto-limbic areas, outside the area of tumor growth. Focal hypothalamic lesions may trigger distal changes in connected brain areas, which then contribute to the above-mentioned impairments, not explicable by a hypothalamic lesion alone.⁷⁹

There is no published data on cognitive and social deficits in patients with adult-onset CP to the best of our knowledge.

Quality of life

Patients with childhood onset CP rated their social and emotional functioning lower than their healthy controls. The most frequent problems reported were difficulties with learning, inability to

control emotions, unsatisfactory peer relationships and concerns regarding their physical appearance. Impairment in QoL was rather psychosocial than physical.⁸⁰ Patient's parents assess their QoL worse than patients themselves.¹²

Adult-onset CP patients score worse than the previous group, but on the contrary, they describe impairments in QoL mainly due to general and physical fatigue, psychological condition and physical mobility. Younger adults reported also social isolation and difficulties in social functioning. Adult-onset patients also performed worse on the depression score than childhood-onset patients. The main independent predictors for decreased QoL were visual field defects, female gender, repeated surgery and HO.^{81,82}

Conclusions

CP is a low grade tumor with locally aggressive behaviour resulting in high morbidity in both children and adults. A multidisciplinary team of neurosurgeons, neuro-radiologists, neuro-oncologists, pathologists and endocrinologists should be involved in the diagnosis, treatment planning and lifelong follow-up of these patients to achieve the best outcomes. The development of a national registry increases the quality of management. At present subtotal resection of the tumor with localized irradiation is the treatment of choice to prevent further complications associated with the hypothalamic damage. Careful pituitary hormone replacement in addition to individualized nutritional intake and regular physical activity planning is essential to decrease the morbidity associated with endocrine and metabolic consequences of the tumor and its management, especially if the hypothalamic region has been significantly damaged. Further studies of the signalling pathways involved in the pathogenesis of the tumor will hopefully give rise to novel treatment modalities, enabling a less aggressive surgical and radiation therapy and possibly better neuroendocrine and metabolic outcomes.

References

1. Bunin GR, Surawicz TS, Witman PA, Preston-Martin S, Davis F, Bruner JM. The descriptive epidemiology of craniopharyngioma. *J Neurosurg* 1998; **89**: 547-51. doi: 10.3171/jns.1998.89.4.0547
2. Nielsen EH, Feldt-Rasmussen U, Poulsen L, Kristensen LO, Astrup J, Jorgensen JO, et al. Incidence of craniopharyngioma in Denmark (n = 189) and estimated world incidence of craniopharyngioma in children and adults. *J Neurooncol* 2011; **104**: 755-63. doi: 10.1007/s11060-011-0540-6

3. Ostrom QT, Gittleman H, Liao P, Vecchione Koval T, Wolinsky Y, Kruchko C, et al. CBTRUS Statistical Report: primary brain and other central nervous system tumors diagnosed in the United States in 2010–2014. *Neuro Oncol* 2017; **19**(Suppl. 5): 1-88. doi: 10.1093/neuonc/nox158
4. Ostrom QT, Gittleman H, Xu J, Kromer C, Wolinsky Y, Kruchko C, et al. CBTRUS statistical report: Primary brain and other central nervous system tumors diagnosed in the United States in 2009–2013. *Neuro Oncol* 2016; **18**: 1-75. doi: 10.1093/neuonc/now207
5. Thapar K, Kovacs K. Neoplasms of the sellar region. Russell and Rubinstein's Pathology of tumors of the nervous system., 6th edition. McLendon RE, Rosenblum MK, Bigner DD, editors. Boca Raton, Florida: CRC Press Taylor & Francis Group; 1998. p. 629-80.
6. Zada G, Lin N, Ojerholm E, Ramkissoon S, Laws ER. Craniopharyngioma and other cystic epithelial lesions of the sellar region: a review of clinical, imaging, and histopathological relationships. *Neurosurg Focus* 2010; **28**: E4. doi: 10.3171/2010.2.FOCUS09318
7. Pascual JM, Prieto R, Rosdolsky M, Strauss S, Castro J, Verena D. Cystic tumors of the pituitary infundibulum: seminal autopsy specimens (1899 to 1904) that allowed clinical-pathological craniopharyngioma characterization. *Pituitary* 2018; **21**: 393-405. doi: 10.1007/s11102-018-0889-z
8. Wijnen M, Van Den Heuvel-Eibrink MM, Janssen JAMJL, Catsman-Berreoets CE, Michiels EMC, Van Veelen-Vincent MLC, et al. Very long-term sequelae of craniopharyngioma. *Eur J Endocrinol* 2017; **176**: 755-67. doi: 10.1530/EJE-17-0044
9. Sterkenburg AS, Hoffmann A, Gebhardt U, Warmuth-Metz M, Daubenbüchel AMM, Müller HL. Survival, hypothalamic obesity, and neuropsychological/psychosocial status after childhood-onset craniopharyngioma: Newly reported long-term outcomes. *Neuro Oncol* 2015; **17**: 1029-38. doi: 10.1093/neuonc/nov044
10. Erfurth EM, Holmer H, Fjalldal SB. Mortality and morbidity in adult craniopharyngioma. *Pituitary* 2013; **16**: 46-55. doi: 10.1007/s11102-012-0428-2
11. Müller HL, Merchant TE, Puget S, Martinez-Barbera JP. New outlook on the diagnosis, treatment and follow-up of childhood-onset craniopharyngioma. *Nat Rev Endocrinol* 2017; **13**: 299-312. doi: 10.1038/nrendo.2016.217
12. Heinks K, Boekhoff S, Hoffmann A, Warmuth-Metz M, Eveslage M, Peng J, et al. Quality of life and growth after childhood craniopharyngioma: results of the multinational trial KRANIOPHARYNGEOM 2007. *Endocrine* 2018; **59**: 364-72. doi: 10.1007/s12020-017-1489-9
13. Karavitaki N, Brufani C, Warner JT, Adams CBT, Richards P, Ansgore O, et al. Craniopharyngiomas in children and adults: systematic analysis of 121 cases with long-term follow-up. *Clin Endocrinol (Oxf)* 2005; **62**: 397-409. doi: 10.1111/j.1365-2265.2005.02231.x
14. Müller HL. Craniopharyngioma - a chronic disease. *Swiss Med Wkly* 2018; **148**: w14548. doi: 10.4414/smw.2017.14548
15. Schoenfeld A, Pekmezci M, Barnes MJ, Tihan T, Gupta N, Lamborn KR, et al. The superiority of conservative resection and adjuvant radiation for craniopharyngiomas. *J Neurooncol* 2012; **8**: 133-9. doi: 10.1007/s11060-012-0806-7
16. Hoffmann A, Warmuth-Metz M, Gebhardt U, Müller H. Childhood craniopharyngioma – changes of treatment strategies in the trials KRANIOPHARYNGEOM 2000/2007. *Klin Padiatr* 2014; **226**: 161-8. doi: 10.1055/s-0034-1368785
17. Ajithkumar T, Mazhari AL, Stickan-Verfürth M, Kramer PH, Fuentes CS, Lambert J, et al. Proton therapy for craniopharyngioma - an early report from a single European centre. *Clin Oncol* 2018; **30**: 307-16. doi: 10.1016/j.clon.2018.01.012
18. Kendall-Taylor P, Jönsson PJ, Abs R, Erfurth EM, Koltowska-Hägström M, Price DA, et al. The clinical, metabolic and endocrine features and the quality of life in adults with childhood-onset craniopharyngioma compared with adult-onset craniopharyngioma. *Eur J Endocrinol* 2005; **152**: 557-67. doi: 10.1530/eje.1.01877
19. Wijnen M, Olsson DS, Van Den Heuvel-Eibrink MM, Hammarstrand C, Janssen JAMJL, Van Der Lely AJ, et al. The metabolic syndrome and its components in 178 patients treated for craniopharyngioma after 16 years of follow-up. *Eur J Endocrinol* 2018; **178**: 11-22. doi: 10.1530/EJE-17-0387
20. Andereggen L, Hess B, Andres RH, El-Koussy M, Mariani L, Raabe A, et al. A ten-year follow-up study of treatment outcome of craniopharyngiomas. *Swiss Med Wkly* 2018; **148**: 1-8. doi: 10.4414/smw.2017.14521
21. Tan TSE, Patel L, Gopal-Kothandapani JS, Ehtisham S, Ikazoboh EC, Hayward R, et al. The neuroendocrine sequelae of paediatric craniopharyngioma: a 40-year meta-data analysis of 185 cases from three UK centres. *Eur J Endocrinol* 2017; **176**: 359-69. doi: 10.1530/EJE-16-0812
22. Bosnjak R, Benedicic M, Vittori A. Early outcome in endoscopic extended endonasal approach for removal of supradiaphragmatic craniopharyngiomas: a case series and a comprehensive review. *Radiol Oncol* 2013; **47**: 266-79. doi: 10.2478/raon-2013-0036
23. Brastianos PK, Shankar GM, Gill CM, Taylor-Weiner A, Nayyar N, Panka, DJ, et al. Dramatic response of BRAF V600E mutant papillary craniopharyngioma to targeted therapy. *J Natl Cancer Inst* 2016; **108**: 1-5. doi: 10.1093/jnci/djv310
24. Himes BT, Ruff MW, Gompel JJ Van, Park SS, Galanis E, Kaufmann TJ, et al. Recurrent papillary craniopharyngioma with dabrafenib: case report. *J Neurosurg* 2018; **1**: 1-5. doi: 10.3171/2017.11.JNS172373
25. Hoffmann A, Boekhoff S, Gebhardt U, Sterkenburg AS, Daubenbüchel AMM, Eveslage M, et al. History before diagnosis in childhood craniopharyngioma: Associations with initial presentation and long-term prognosis. *Eur J Endocrinol* 2015; **173**: 853-62. doi: 10.1530/EJE-15-0709
26. Mortini P, Losa M, Pozzobon G, Barzagli R, Riva M, Acerno S, et al. Neurosurgical treatment of craniopharyngioma in adults and children: early and long-term results in a large case series. *J Neurosurg* 2011; **114**: 1350-9. doi: 10.3171/2010.11.JNS10670
27. Crotty TB, Scheithauer BW, Young WF, Davis DH, Shaw EG, Miller GM, et al. Papillary craniopharyngioma: a clinicopathological study of 48 cases. *J Neurosurg* 1995; **83**: 206-14. doi: 10.3171/jns.1995.83.2.0206
28. Müller HL. Hypothalamic involvement in craniopharyngioma—Implications for surgical, radiooncological, and molecularly targeted treatment strategies. *Pediatr Blood Cancer* 2018; **65**: e26936. doi: 10.1002/pbc.26936
29. Roth CL, Eslamy H, Werny D, Elfers C, Shaffer ML, Pihoker C, et al. Semiquantitative analysis of hypothalamic damage on MRI predicts risk for hypothalamic obesity. *Obesity* 2015; **23**: 1226-33. doi: 10.1002/oby.21067
30. Mortini P, Gagliardi F, Bailo M, Spina A, Parlangei A, Falini A, et al. Magnetic resonance imaging as predictor of functional outcome in craniopharyngiomas. *Endocrine* 2016; **51**: 148-62. doi: 10.1007/s12020-015-0683-x
31. Müller HL. Craniopharyngioma and hypothalamic injury: latest insights into consequent eating disorders and obesity. *Curr Opin Endocrinol Diabetes Obes* 2016; **23**: 81-9. doi: 10.1097/MED.0000000000000214
32. Pascual JM, Prieto R, Carrasco R, Barrios L. Displacement of mammillary bodies by craniopharyngiomas involving the third ventricle: surgical-MRI correlation and use in topographical diagnosis. *J Neurosurg* 2013; **119**: 381-405. doi: 10.3171/2013.1.JNS111722
33. Zoicas F, Schöfl C. Craniopharyngioma in adults. *Front Endocrinol (Lausanne)* 2012; **3**: 46. doi: 10.3389/fendo.2012.00046
34. Amelot A, Borha A, Calmon R, Barbet P, Puget S. Child dermoid cyst mimicking a craniopharyngioma: the benefit of MRI T2-weighted diffusion sequence. *Child's Nerv Syst* 2018; **34**: 359-62. doi: 10.1007/s00381-017-3602-z
35. Puget S, Garnett M, Wray A, Grill J, Habrand JL, Bodaert N, et al. Pediatric craniopharyngiomas: classification and treatment according to the degree of hypothalamic involvement. *J Neurosurg Pediatr* 2007; **106**: 3-12. doi: 10.3171/ped.2007.106.1.3
36. Elowe-Gruau E, Beltrand J, Brauner R, Pinto G, Samara-Boustani D, Thalassinou C, et al. Childhood craniopharyngioma: hypothalamus-sparing surgery decreases the risk of obesity. *J Clin Endocrinol Metab* 2013; **98**: 2376-82. doi: 10.1210/jc.2012-3928
37. Weiner HL, Wisoff JH, Rosenberg ME, Kupersmith MJ, Cohen H, Zagzag D, et al. Craniopharyngiomas: a clinicopathological analysis of factors predictive of recurrence and functional outcome. *Neurosurgery* 1994; **35**: 1001-11. http://dx.doi.org/10.1227/0006123-199412000-00001.
38. Müller HL, Gebhardt U, Teske C, Faldum A, Zwiener I, Warmuth-Metz M, et al. Post-operative hypothalamic lesions and obesity in childhood craniopharyngioma: results of the multinational prospective trial KRANIOPHARYNGEOM 2000 after 3-year follow-up. *Eur J Endocrinol* 2011; **165**: 17-24. doi: 10.1530/EJE-11-0158
39. Gu Y, Zhang X. Letter to the Editor: mammillary body angle and craniopharyngioma. *J Neurosurg* 2014; **120**: 1241-5. doi: 10.3171/2013.11.JNS132343
40. Coury JR, Davis BN, Koumas CP, Manzano GS, Dehdashti AR. Histopathological and molecular predictors of growth patterns and recurrence in craniopharyngiomas: a systematic review. *Neurosurg Rev* 2018. doi: 10.1007/s10143-018-0978-5
41. Karavitaki N, Cudlip S, Adams CB, and Wass JA. Craniopharyngiomas. *Endocr Rev* 2006; **27**: 371-97. doi: 10.1210/er.2006-0002
42. Clark AJ, Cage TA, Aranda D, Parsa AT, Sun PP, Auguste KI, et al. A systematic review of the results of surgery and radiotherapy on tumor control for pediatric craniopharyngioma. *Child's Nerv Syst* 2013; **29**: 231-8. doi: 10.1007/s00381-012-1926-2

43. Kiehna EN, Merchant TE. Radiation therapy for pediatric craniopharyngioma. *Neurosurg Focus* 2010; **28**: E10. doi: 10.3171/2010.1.FOCUS09297
44. O'steen L, Indelicato DJ. Advances in the management of craniopharyngioma. *F1000Research* 2018; **7**: 1632. doi:10.12688/f1000research.15834.1
45. Kortmann RD. Different Approaches in Radiation Therapy of Craniopharyngioma. *Front Endocrinol (Lausanne)* 2011; **2**: 100. doi: 10.3389/fendo.2011.00100
46. Bishop AJ, Greenfield B, Mahajan A, Paulino AC, Okcu MF, Allen, PK, et al. Proton beam therapy versus conformal photon radiation therapy for childhood craniopharyngioma: Multi-institutional analysis of outcomes, cyst dynamics, and toxicity. *Int J Radiat Oncol Biol Phys* 2014; **90**: 354-61. doi: 10.1016/j.ijrobp.2014.05.051
47. Harrabi SB, Aberg S, Welzel T, Rieken S, Habermehl D, Debus J, et al. Long term results after fractionated stereotactic radiotherapy (FSRT) in patients with craniopharyngioma: maximal tumor control with minimal side effects. *Radiat Oncol* 2014; **9**: 203. doi: 10.1186/1748-717X-9-203
48. Beltran C, Roca M, Merchant TE. On the Benefits and Risks of Proton Therapy in Pediatric Craniopharyngioma. *Int J Radiat Oncol* 2012; **82**: 281-7. doi: 10.1016/j.ijrobp.2011.01.005
49. Regine WF, Kramer S. Pediatric craniopharyngiomas: Long term results of combined treatment with surgery and radiation. *Int J Radiat Oncol* 1992; **24**: 611-17. doi: 10.1016/0360-3016(92)90705-M
50. Winkfield KM, Linsenmeier C, Yock TI, Grant PE, Yeap BY, Butler WE, et al. Surveillance of Craniopharyngioma Cyst Growth in Children Treated With Proton Radiotherapy *Int J Radiat Oncol* 2009; **73**: 716-21. doi: https://doi.org/10.1016/j.ijrobp.2008.05.010
51. Losa M, Pieri V, Bailo M, Gagliardi F, Barzaghi LR, Gioia L, et al. Single fraction and multisession Gamma Knife radiosurgery for craniopharyngioma. *Pituitary* 2018; **21**: 499-506. doi: 10.1007/s11102-018-0903-5
52. Buslei R, Nolde M, Hofmann B, Meissner S, Eyupoglu IY, Siebzehrnrl F, et al. Common mutations of β -catenin in adamantinomatous craniopharyngiomas but not in other tumours originating from the sellar region. *Acta Neuropathol* 2005; **109**: 589-97. doi: 10.1007/s00401-005-1004-x
53. Pekmezci M, Louie J, Gupta N, Bloomer MM, Tihan T. Clinicopathological characteristics of adamantinomatous and papillary craniopharyngiomas: University of California, San Francisco experience 1985-2005. *Neurosurgery* 2010; **67**: 1341-9. doi: 10.1227/NEU.0b013e3181f2b583
54. Prieto R, Pascual JM. Can tissue biomarkers reliably predict the biological behavior of craniopharyngiomas? A comprehensive overview. *Pituitary* 2018; **21**: 431-42. doi: 10.1007/s11102-018-0890-6
55. Apps JR, Martinez-Barbera JP. Molecular pathology of adamantinomatous craniopharyngioma: review and opportunities for practice. *Neurosurg Focus* 2016; **41**: E4. doi: 10.3171/2016.8.FOCUS16307
56. Brastianos PK, Taylor-Weiner A, Manley PE, Robert T, Dias-Santagata D, Thorner AR, et al. Exome sequencing identifies BRAF mutations in papillary craniopharyngiomas. *Nat Genet* 2014; **46**: 161-5. doi: 10.1038/ng.2868
57. Apps JR, Carreno G, Gonzalez-Meljem JM, Haston S, Guiho R, Cooper JE, et al. Tumour compartment transcriptomics demonstrates the activation of inflammatory and odontogenic programmes in human adamantinomatous craniopharyngioma and identifies the MAPK/ERK pathway as a novel therapeutic target. *Acta Neuropathol* 2018; **135**: 757-77. doi: 10.1007/s00401-018-1830-2
58. Davies H, Bignell GR, Cox C, Stephens P, Edkins S, Clegg S, et al. Mutations of the BRAF gene in human cancer. *Nature* 2002; **417**: 949. doi: 10.1038/nature00766
59. Larkin SJ, Preda V, Karavitaki N, Grossman A, Ansgore O. BRAF V600E mutations are characteristic for papillary craniopharyngioma and may coexist with CTNNB1-mutated adamantinomatous craniopharyngioma. *Acta Neuropathol* 2014; **127**: 927-9. doi: 10.1007/s00401-014-1270-6
60. Bi WL, Larsen AG, Dunn IF. Genomic Alterations in Sporadic Pituitary Tumors. *Curr Neurol Neurosci Rep* 2018; **18**: 4. doi: 10.1007/s11910-018-0811-0
61. Aylwin SJB, Bodi I, Beaney R. Pronounced response of papillary craniopharyngioma to treatment with vemurafenib, a BRAF inhibitor. *Pituitary* 2016; **19**: 544-6. doi: 10.1007/s11102-015-0663-4
62. Roque A, Oda Y. BRAF-V600E mutant papillary craniopharyngioma dramatically responds to combination BRAF and MEK inhibitors. *CNS Oncol* 2017; **6**: 95-9. doi: 10.2217/cns-2016-0034
63. Rostami E, Witt Nyström P, Libard S, Wikström J, Casar-Borota O, Gudjonsson O. Recurrent papillary craniopharyngioma with BRAFV600E mutation treated with neoadjuvant-targeted therapy. *Acta Neurochir (Wien)* 2017; **159**: 2217-21. doi: 10.1007/s00701-017-3311-0
64. Caldarelli M, Massimi L, Tamburrini G, Cappa M, Di Rocco C. Long-term results of the surgical treatment of craniopharyngioma: the experience at the Policlinico Gemelli, Catholic University, Rome. *Child's Nerv Syst* 2005; **21**: 747-57. doi: 10.1007/s00381-005-1186-5
65. Müller HL. Childhood craniopharyngioma. *Pituitary* 2013; **16**: 56-67. doi: 10.1007/s11102-012-0401-0
66. Boekhoff S, Bogusz A, Sterkenburg AS, Eveslage M, Müller HL. Long-term effects of growth hormone replacement therapy in childhood-onset craniopharyngioma: results of the German Craniopharyngioma Registry (HIT-Endo). *Eur J Endocrinol* 2018; **179**: 331-41. doi: 10.1530/EJE-18-0505.
67. Geffner ME. The growth without growth hormone syndrome. *Endocrinol Metab Clin* 1996; **25**: 649-63. doi: 10.1016/S0889-8529(05)70345-5
68. Holmer H, Pozarek G, Wirfält E, Popovic V, Ekman B, Björk J, et al. Reduced energy expenditure and impaired feeding-related signals but not high energy intake reinforces hypothalamic obesity in adults with childhood onset craniopharyngioma. *J Clin Endocrinol Metab* 2010; **95**: 5395-402. doi: 10.1210/jc.2010-0993
69. Bereket A, Kiess W, Lustig RH, Müller HL, Goldstone AP, Weiss R, et al. Hypothalamic obesity in children. *Obes Rev* 2012; **13**: 780-98. doi: 10.1111/j.1467-789X.2012.01004
70. Hoffmann A, Bootsvelde K, Gebhardt U, Daubenbüchel AMM, Sterkenburg AS, Müller HL. Nonalcoholic fatty liver disease and fatigue in long-term survivors of childhood-onset craniopharyngioma. *Eur J Endocrinol* 2015; **173**: 389-97. doi: 10.1530/EJE-15-0422
71. Tomlinson JW, Holden N, Hills RK, Wheatley K, Clayton RN, Bates AS, et al. Association between premature mortality and hypopituitarism. *Lancet* 2001; **357**: 425-31. doi: 10.1016/S0140-6736(00)04006-X
72. Rosén T, Bengtsson BA. Premature mortality due to cardiovascular disease in hypopituitarism. *Lancet* 1990; **336**: 285-8. doi: 10.1016/0140-6736(90)91812-0
73. Bülow B, Attewell R, Hagmar L, Malmström P, Nordström CH, Erfurth EM. Postoperative prognosis in craniopharyngioma with respect to cardiovascular mortality, survival, and tumor recurrence. *J Clin Endocrinol Metab* 1998; **83**: 3897-904. doi: 10.1210/jc.83.11.3897
74. Holmer H, Ekman B, Björk J, Nordström CH, Popovic V, Siversson AB, et al. Hypothalamic involvement predicts cardiovascular risk in adults with childhood onset craniopharyngioma on long-term GH therapy. *Eur J Endocrinol* 2009; **161**: 671-9. doi: 10.1530/EJE-09-0449
75. Defoort-Dhellemmes S, Moritz F, Bouacha I, Vinchon M. Craniopharyngioma: ophthalmological aspects at diagnosis. *J Pediatr Endocrinol Metab* 2006; **19**(Suppl 1): 321-4. <http://europepmc.org/abstract/MED/16700306>
76. Pierre-Kahn A, Recassens C, Pinto G, Thalassinos C, Chokron S, Soubervielle JC, et al. Social and psycho-intellectual outcome following radical removal of craniopharyngiomas in childhood. A prospective series. *Child's Nerv Syst* 2005; **21**: 817-24. doi: 10.1007/s00381-005-1205-6
77. Riva D, Pantaleoni C, Devoti M, Saletti V, Nichelli F, Giorgi C. Late neuropsychological and behavioural outcome of children surgically treated for craniopharyngioma. *Child's Nerv Syst* 1998; **14**: 179-84. doi: 10.1007/s003810050207
78. Özyurt J, Müller HL, Warmuth-Metz M, Thiel CM. Hypothalamic tumors impact gray and white matter volumes in fronto-limbic brain areas. *Cortex* 2017; **89**: 98-110. doi: 10.1016/j.cortex.2017.01.017
79. Poretti A, Grotzer MA, Ribi K, Schonle E, Boltshauser E. Outcome of craniopharyngioma in complications and quality of life. *Dev Med Child Neurol* 2004; **46**: 220-9. doi: 10.1111/j.1469-8749.2004.tb00476.x
80. Dekkers OM, Biermasz NR, Smith JWA, Groot LE, Roelfsema F, Romijn JA, et al. Quality of life in treated adult craniopharyngioma patients. *Eur J Endocrinol* 2006; **154**: 483-9. doi: 10.1530/eje.1.02114
81. Gautier A, Godbout A, Grosheny C, Tejedor I, Coudert M, Courtillot C, et al. Markers of recurrence and long-term morbidity in craniopharyngioma: a systematic analysis of 171 patients. *J Clin Endocrinol Metab* 2012; **97**: 1258-67. doi: 10.1210/jc.2011-2817
82. van Iersel L, Meijneke RWH, Schouten-van Meeteren AYN, Reneman L, de Win MM, van Trotsenburg ASP, et al. The development of hypothalamic obesity in craniopharyngioma patients: a risk factor analysis in a well-defined cohort. *Pediatr Blood Cancer* 2018; **65**: e26911. doi: 10.1002/pbc.26911
83. Borrill R, Cheesman E, Stivaros S, Kamaly-Asl ID, Gnanalingham K, Kilday J-P. Papillary craniopharyngioma in a 4-year-old girl with BRAF V600E mutation: a case report and review of the literature. *Child's Nerv Syst* 2019; **35**: 169-73. doi:10.1007/s00381-018-3925-4.