

Diagnostic performance of tomosynthesis, digital mammography and a dedicated digital specimen radiography system versus pathological assessment of excised breast lesions

Sa'ed Almasarweh^{1,2,3}, Mazen Sudah^{1,2}, Hidemi Okuma¹, Sarianna Joukainen⁴, Vesa Kärjä⁵, Ritva Vanninen^{1,2}, Amro Masarwah^{1,2}

¹ Department of Clinical Radiology, Diagnostic Imaging Center, Kuopio University Hospital, Kuopio, Finland

² Clinical Radiology, Institute of Clinical Medicine, School of Medicine, University of Eastern Finland, Kuopio, Finland

³ Department of Gynecology and Obstetrics, Essen University Hospital, Essen, Germany

⁴ Department of Plastic Surgery, Division of Surgery, Kuopio University Hospital, Kuopio, Finland

⁵ Department of Clinical pathology, Diagnostic Imaging Center, Kuopio University Hospital, Kuopio, Finland

Radiol Oncol 2022; 56(4): 461-470.

Received 23 May 2022

Accepted 6 July 2022

Correspondence to: Sa'ed Almasarweh, M.D., Department of Obstetrics and Gynaecology, Essen University Hospital, Hufelandstraße 55, D-45147 Essen, Germany. E-mail: saed.almasarweh@uk-essen.de; Phone: +49 (201) 723 2241

Disclosure: No potential conflicts of interest were disclosed.

This is an open access article distributed under the terms of the CC-BY license (<https://creativecommons.org/licenses/by/4.0/>).

Background. The aim of the study was to compare the performance of full-field digital mammography (FFDM), digital breast tomosynthesis and a dedicated digital specimen radiography system (SRS) in consecutive patients, and to compare the margin status of resected lesions versus pathological assessment.

Patients and methods. Resected tissue specimens from consecutive patients who underwent intraoperative breast specimen assessment following wide local excision or oncoplastic breast conservative surgery were examined by FFDM, tomosynthesis and SRS. Two independent observers retrospectively evaluated the visibility of lesions, size, margins, spiculations, calcifications and diagnostic certainty, and chose the best performing method in a blinded manner.

Results. We evaluated 216 specimens from 204 patients. All target malignant lesions were removed with no tumour-on-ink. One papilloma had positive microscopic margins and one patient underwent reoperation owing to extensive *in situ* components. There were no significant differences in measured lesion size among the three methods. However, tomosynthesis was the most accurate modality when compared with the final pathological report. Both observers reported that tomosynthesis had significantly better lesion visibility than SRS and FFDM, which translated into a significantly greater diagnostic certainty. Tomosynthesis was superior to the other two methods in identifying spiculations and calcifications. Both observers reported that tomosynthesis was the best performing method in 76.9% of cases. The interobserver reproducibilities of lesion visibility and diagnostic certainty were high for all three methods.

Conclusions. Tomosynthesis was superior to SRS and FFDM for detecting and evaluating the target lesions, spiculations and calcifications, and was therefore more reliable for assessing complete excision of breast lesions.

Key words: breast cancer; radiography; digital breast tomosynthesis; surgery; mammography

Introduction

Breast conserving surgery (BCS) is an established treatment modality for early breast cancer, offer-

ing better aesthetic results and less morbidity, without compromising survival, compared with radical mastectomy.^{1,2}

A clear resection margin after surgical excision is associated with a reduced risk of local recurrence. Positive margins are associated with a 2-fold increased risk of ipsilateral recurrence.³ This risk is not eliminated by radiotherapy, systemic chemotherapy or endocrine therapy. Therefore, to achieve the best local disease-free survival, a negative margin must be achieved during surgery and confirmed by the final microscopic assessment of the excised tissue.

The published reoperation rates for patients with early stage breast cancer vary considerably, between 10% and 60%, depending on the treating centre and the surgeon's practice, with an average rate of ~20%.⁴ To reduce the rate of reoperation in patients with non-palpable lesions, intraoperative assessment is performed to confirm adequate removal of the detected lesions and margin. The resected sample is imaged, most commonly by digital mammography, while the patient is under general anaesthesia. The images are analysed and information about the resection margins is given to the surgeon. Proper assessment of the margins reduces the need for reoperation, the cost of hospital stay and the subsequent psychological or cosmetic impact on the patient. Failure to achieve negative margins usually results in re-excision or mastectomy.⁵

Digital breast tomosynthesis eliminates tissue superimposition and provides a clearer view of dense breasts because it provides three-dimensional (3D) images unlike mammography, which provides two-dimensional (2D) images.⁶ Specimen tomosynthesis was previously shown to be superior to digital mammography for depicting excised lesions and evaluation of resection margins.⁷⁻¹³ Mobile, dedicated digital specimen radiography is a rapid method for intraoperative specimen assessment that can image the excised specimen in the operating room, thus avoiding the need to send the specimen to the radiology department. This shortens the duration of anaesthesia, reducing morbidity and mortality, and decreases operating room occupancy, thus reducing costs, while still providing comparable results to digital mammography.¹⁴⁻¹⁶

The aim of this study was to directly compare the diagnostic performance of full-field digital mammography (FFDM), digital breast tomosynthesis and a dedicated digital specimen radiography system (SRS) for the evaluation of resected breast lesions in consecutive patients, and to compare the margin status of resected lesions versus the final pathological report.

Patients and methods

This study was undertaken as part of the continuous improvement, quality control and internal validation of modern surgical specimen imaging technologies at the Breast Unit at Kuopio University Hospital (Kuopio, Finland). During the study period, clinical decisions concerning lesion removal and margin status were made by experienced breast radiologists and surgeons and based on all available images.

The detailed analyses and intertechnique comparisons described here were performed retrospectively and did not affect patient management. The Chair of the hospital district waived the need to obtain written informed consent from the patients owing to the retrospective nature of the analyses (Approval: FinMargins 5063573; 508/2021). All clinical investigations were conducted according to the relevant guidelines and the principles expressed in the Declaration of Helsinki.

Study population

The study population comprised all consecutive patients who required radiological intraoperative breast specimen assessment at our tertiary university hospital between April 2018 and December 2019. Patients were included in this study if they were diagnosed with invasive breast cancer, ductal carcinoma *in situ* (DCIS) or high-risk and atypical lesions and had been referred to our tertiary university hospital for further evaluation and breast surgery.

All patients were evaluated preoperatively with a minimum of a two-view mammogram and ultrasound. Any suspicious lesions were evaluated using additional lateral and spot-compression views. All mammograms were re-evaluated upon referral by an experienced, specialist senior breast radiologist, and further workup was performed if deemed necessary. Breast magnetic resonance imaging is not routinely performed preoperatively in all patients at our centre; instead, it is performed according to national guidelines that are in concordance with the European Society of Breast Cancer Specialists' recommendations.¹⁷ Patients underwent ultrasound-guided core biopsy or stereotactic vacuum-assisted biopsy and were histologically diagnosed with breast cancer and high-risk or atypical lesions before surgery. If lesions were found in both breasts, each specimen was evaluated separately. Patients who underwent neoadjuvant chemotherapy were excluded from this

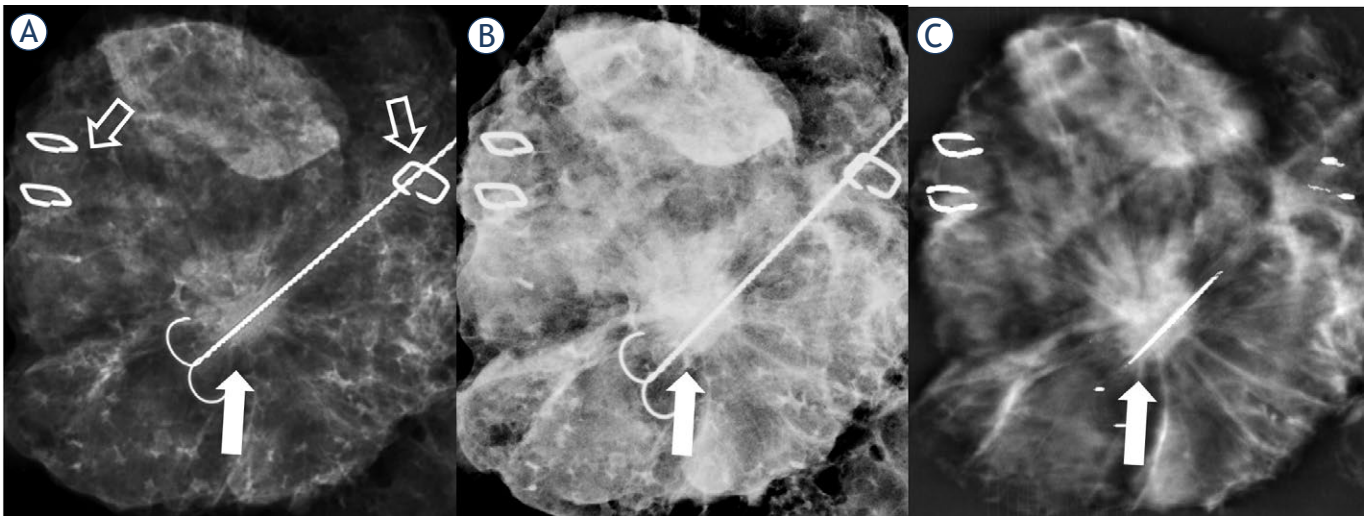


FIGURE 1. Specimen radiographs of a spiculated invasive ductal carcinoma excised after ultrasound guidewire localisation. The tumour and spicules are clearly visible in all three imaging modalities (closed arrows). (A) Specimen radiography system, (B) full-field digital mammography and (C) tomosynthesis (1 mm reconstructed image at the level of the tumour). Metal clips indicate the anatomical position (open arrows; 1 clip-lateral and 2 clips-medial). The position of the specimen is constant in all three imaging modalities.

study. The final analyses comprised 216 specimens from 204 women (mean age 62.5 ± 10.6 years, range 33–95 years).

Lesion localisation and surgery

The surgical procedure was planned individually according to the patient's preference, tumour size, tumour location, clinical findings, breast shape and breast size. All patients were evaluated at multidisciplinary meetings, at least twice, pre- and postoperatively.

Non-palpable tumours were localised pre-operatively using at least one guidewire (breast localization needle Duo, SOMATEX® Medical Technologies GmbH) under ultrasound or stereotactic guidance. Two-view mammography (CC and lateromedial) was routinely performed to confirm the position of each lesion relative to the guidewire, and the location of the lesion was ink-marked on the skin, including supine MRI-guided localisation projections.¹⁸ Tumours were excised en bloc from the subcutaneous area to the muscle, and the overlying skin was removed in patients with superficial lesions to achieve a healthy macroscopic surgical margin of ≥ 1 cm, in accordance with national guidelines, and hence achieve microscopically negative margins (defined as no "tumour-on-ink"). In ductal carcinoma in-situ (DCIS), the need for reoperation is evaluated in a multidisciplinary meeting whenever DCIS margins are less than 2 mm. Intraoperatively, the

specimens were placed on a Styrofoam slab, fixed with wooden sticks, and the location of the excision was anatomically marked. Metallic clips were placed directly on the specimen to indicate the orientation. The fascia posterior to the tumour was removed and fixed aside if removed separately (Figure 1, 2). The specimen was then placed in a plastic container and immediately transported to the Breast Radiology Unit.

Imaging protocol

Each specimen was first imaged by 2D FFDM in craniocaudal and lateral projections (Selenia Dimensions® breast tomosynthesis system, Hologic Inc., Bedford) followed immediately by tomosynthesis (images reconstructed into a series of 1-mm-thick slices at 1-mm intervals) and radiography using a dedicated digital SRS (Xpert 40; Kubtec Medical Imaging, Stratford, CT). The specimen was imaged bare, without tissue compression, in all three modalities.

Retrospective image analysis

All images were stored in the regional picture archiving and communication system and were evaluated retrospectively by two radiologists, with 12 and 2 years of experience, in a blind, independent manner. In order to minimise possible bias, the observers analysed the images obtained by each modality separately, presented in a random order,

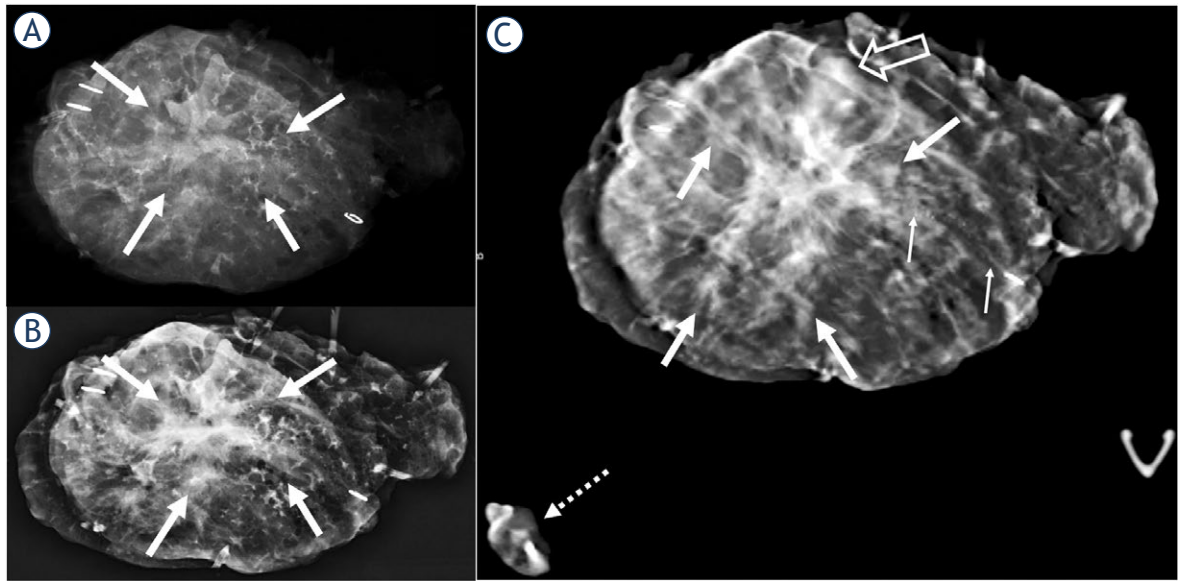


FIGURE 2. A 44-year-old female presented with a 5 × 4.5 cm multifocal invasive lobular carcinoma and underwent supine magnetic resonance imaging-guided oncoplastic conservative resection. Although the irregular area of the tumour (thick arrows) is visible on the specimen radiography system (A) and full-field digital mammography (B) images, the tumour margins are best delineated by tomosynthesis (C) (1 mm reconstructed image at the level of the tumour). The pleomorphic lobular carcinoma *in situ* is clearly depicted by tomosynthesis as an area of linear calcifications (thin arrows). The shortest margins at imaging were 4 mm (open arrow; superior) and 5 mm at final pathology. The fascia at the level of tumour was removed separately (dotted arrow).

with a short interval before analysing the images obtained from the next modality, which was also presented in a random order. Both observers were blinded to the clinical and pathological features of the lesions and were only allowed to refer to the preoperative images when assessing each image. The detectability and visibility of the main lesions, margins, spiculations and calcifications, measured lesion size and diagnostic certainty were recorded using 5-point scales for each modality. In a final session, the observers independently evaluated all images simultaneously and decided which method performed best in their subjective opinion. Specimen radiography was not routinely performed for additional intraoperative resections, and margin analysis was evaluated and compared with the pathological assessment of the primary resected specimen.

Mammographic features were described according to the 5th edition of the Breast Imaging Reporting and Data System (BI-RADS) by the senior radiologist as masses, calcifications, asymmetry, and architectural distortion. Masses were further classified by their shape and margins, and calcifications were further classified by their morphology and distribution. The amount of peritumoral fibroglandular tissue was documented in quartile percentages.

Histopathological evaluation

The specimens were measured, photographed, margins ink-marked and sliced upon arrival at 5-mm intervals. All macroscopically detected and/or guidewire localised areas were examined meticulously under a microscope and the size and characteristics of each tumour were reported separately. The extent of involvement between the invasive and/or *in situ* cancer in each margin was reported in all six directions. The histopathological data, including the margin status, tumour size, histological grade, estrogen receptor status, progesterone receptor status, human epidermal growth factor receptor 2 status and Ki-67 index, were obtained from the structured histopathological reports.

Statistical analysis

All statistical analyses were performed with SPSS for Windows version 27 (IBM Corporation, Armonk, NY, USA). *P* values of < 0.05 were considered to be statistically significant. The interclass correlation analysis (ICC) was used to evaluate the agreement between lesion visibility and diagnostic certainty recorded by both observers. Pearson's correlation coefficient was used to assess the linear association between the diameters measured

TABLE 1. Characteristics of the patients, surgical procedures and tumours

Mean age years (range)	62.5 (33–95)
Mammography negative	20 (9.3%)
Surgery	
Wide local excision	158 (73.1%)
Oncoplastic	58 (26.9%)
Specimen diameter (mm)	
Mean	97.65
Median	89.0
Range	25–285
Histology n (%)	
Invasive ductal	120 (55.6%)
Invasive lobular	27 (12.5%)
Mixed malignant	7 (3.2%)
Pure DCIS	26 (12.0%)
Other malignant	11 (5.1%)
Benign	25 (11.6%)
Size of tumour mean mm (range)	15.69 (0–70)
Presence of DCIS	114 (52.8%)
Grade	
1	62 (28.7%)
2	94 (43.5%)
3	35 (16.2%)
T-stage	
Tis	27 (14.1%)
T1	122 (63.9%)
T2	40 (20.9%)
T3	2 (1.0%)
N-Stage	
N0	145 (75.9%)
N1	39 (20.4%)
N2	6 (3.1%)
N3	1 (0.5%)
ER-Status	
Positive	152 (92.2%)
Negative	13 (7.8%)
PR-Status	
Positive	147 (89.2%)
Negative	18 (10.8%)
HER2-Status	
Positive	12 (7.3%)
Negative	153 (92.7)

DCIS = ductal carcinoma *in situ*; ER = estrogen receptor; HER2 = human epidermal growth factor receptor 2; N = node; PR = progesterone receptor; T = tumour;

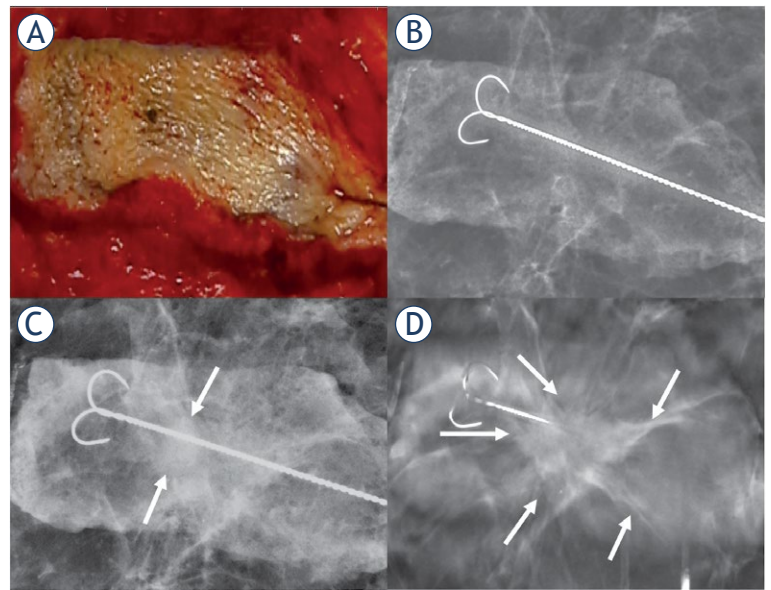


FIGURE 3. A 68-year-old female presented with invasive ductal carcinoma, papillary ductal carcinoma *in situ*, and papillomatosis, and underwent oncoplastic conservative breast resection. (A) Shows the excised skin area above the tumour that was deemed not visible by both observers on the specimen radiography system image (B). (C) Full-field digital mammography shows a small oval lesion (arrow). (D) Tomosynthesis (1 mm reconstructed image) shows the full extension of the large spiculated area (arrows).

using the imaging modalities and histopathology. Bland–Altman analysis and plots were used to assess the differences between mean diameters, as measured by the observers and histopathology, among the two observers.

Results

The final analyses included 204 patients with a mean age of 62.5 years (range 33–95 years). The patient characteristics, histological diagnosis and surgical procedures are presented in Table 1. The majority of lesions were treated by wide local excision (158/216, 73.1%), and oncoplastic conservative breast resection was performed for more than a quarter of lesions (58/216, 26.9%). The mammographic features of the lesions are presented in Table 2.

Regarding interobserver agreement, the ICC was high for lesion visibility (0.787) and diagnostic certainty (0.684) with tomosynthesis. Similar results were observed for SRS and FFDM, with ICCs of 0.742 and 0.804 for lesion visibility and 0.671 and 0.683 for diagnostic certainty, respectively.

As shown in Table 3, both observers felt that tomosynthesis was the best performing imaging

TABLE 2. Mammographic features and lesion descriptors according to the Breast Imaging Reporting and Data System, 5th Edition

Breast density							
A	57	B	121	C	34	D	4
Peritumoral density %							
< 25%	90	25%–50%	20	50%–75%	24	75%–100%	60
Mass Shape							
Oval	17	Round	70	Irregular	58		
Mass Margin							
Circumscribed	4	Obscured	7	Microlobulated	36		
Indistinct	27	Spiculated	71				
Calcifications							
Amorphous	2		Fine Pleomorphic		42		
Coarse Heterogenous	2		Fine linear or branching		7		
Calcification distribution							
Regional	9		Linear		6		
Grouped	33		Segmental		5		
Architectural Distortion							
Yes	15		No		201		

modality in 76.9% of cases (Figure 2, 3). SRS was the least favoured method, chosen only once (0.5%) by observer 1 and six times by observer 2 (2.8%).

Table 4 presents the results reported by both observers. For both observers, tomosynthesis provided significantly better lesion visibility than SRS and FFDM, which translated into a significantly greater diagnostic certainty. Moreover, tomosynthesis was superior to the other two methods for identifying spiculations and calcifications. The high performance of tomosynthesis was not affected by peritumoral density ($p = 0.851$).

All three methods showed comparable results for estimating the diameters of the excised lesions (Table 5). Observer 1, who was more experienced, estimated the lesion sizes with greater accuracy relative to the final pathological report than ob-

server 2, who was less experienced and tended to overestimate the lesion sizes using all three methods. The Pearson's correlation coefficient for tomosynthesis relative to the final pathology was greater than those for SRS and FFDM. The Bland-Altman plots constructed using the lesion diameters measured by the three imaging methods relative to the final pathological report are shown in Figure 4 for both observers. The plots illustrate the greater accuracy of observer 1 compared with the less-experienced observer 2, as well as the superior agreement of tomosynthesis to the final pathological report. The plots also indicate that the differences in measurements increase with increasing lesion diameter for each imaging modality.

Of 204 patients included in this study, only one underwent reoperation owing to inadequate margins. Small invasive ductal carcinoma foci were associated with a 6.5 × 5.5 cm DCIS close to three margins. Upon re-resection, a 2.5 cm residual grade 3 DCIS was found. Intraoperative findings revealed multicentric disease in one patient that was confirmed by pathological assessment of frozen section, and mastectomy was performed. The margins of that specimen were found to be macroscopically and microscopically adequate. One patient with papilloma had a small, microscopic extension to the edge of the specimen. In addition, nine cancers (one DCIS, one invasive lobular and seven invasive ductal cancers) that were not vis-

TABLE 3. The preferred imaging modalities for individual lesions selected by the two observers

	Observer 1	Observer 2
Tomosynthesis	166 (76.9%)	166 (76.9%)
SRS	1 (0.5%)	6 (2.8%)
FFDM	21 (9.7%)	14 (6.5%)
All equal	5 (2.3%)	12 (5.6%)
None	23 (10.6%)	18 (8.3%)

FFDM = full-field digital mammography; SRS = specimen radiography system

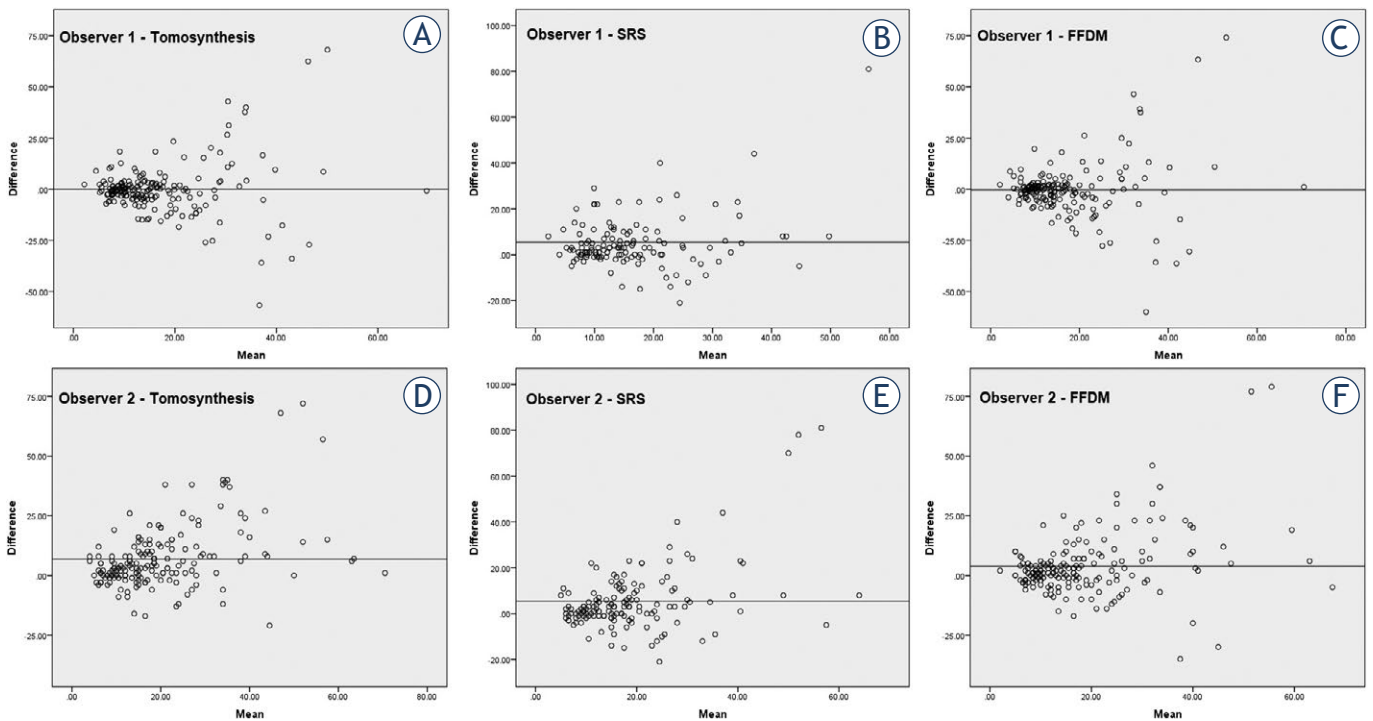


FIGURE 4. Bland-Altman plots of tumour diameters compared with the pathological report, as measured by observer 1 (A-C) and observer 2 (D-F) using tomosynthesis (A,D), specimen radiography system (B,E), and full-field digital mammography (C,F).

FFDM = full-field digital mammography; SRS = specimen radiography system

ible on preoperative imaging were found on the marginal resection specimens removed by the surgeons for cosmetic or additional marginal purposes; all nine had negative margins.

Discussion

Intraoperative assessment of resected specimens is particularly important for successful BCS. To the best of our knowledge, this study is the first to compare the performance of three imaging modalities performed simultaneously in the same patients. Of the three modalities, digital tomosynthesis was superior for visualising lesions, calcifications and spiculations in the majority of specimens, and therefore provided the best confirmation of complete removal of the target lesion. Moreover, both observers, with different levels of experience, felt that tomosynthesis was the superior imaging modality for the majority of cases and reported greater certainty of diagnosis compared with the use of FFDM and SRS.

The cross-sectional capability of tomosynthesis reduces the effect of breast tissue superimposition and therefore helps to delineate the tumour mar-

gins. In this study, tomosynthesis was superior to the other imaging modalities, regardless of the fact that the majority of our patients had fatty breasts (BI-RADS density A or B) and approximately two-thirds of the lesions had low peritumoral tissue densities. This may reflect the better image quality of tomosynthesis compared with 2D techniques. Our results are in concordance with those of prior studies.^{12,13,19}

The underperformance of SRS is noticeable because it did not visualise one in five lesions. Prior studies showed that using mobile SRS in an operating theatre reduced the duration and cost of surgery significantly^{9,14-16}, at the expense of inferior image quality.¹⁴ However, a mobile SRS equipped with tomosynthesis exhibited greater accuracy than standard mammography and reduced the rate of re-excision.¹¹

The reoperation rate after BCS varied markedly in earlier studies. Tumour-related factors that may influence decisions regarding reoperation include focality, presence of DCIS and tumour size⁴, and non-tumour-related factors include inadequate assessment of the extent of macroscopic disease at diagnosis, inaccurate impalpable disease localisation and limited use of intraoperative specimen radi-

TABLE 4. Evaluated parameters of the specimen with three different imaging modalities by both observers

Margins	> 10mm		6–10		≤ 5mm					
Observer	1	2	1	2	1	2				
Tomosynthesis	156	114	20	37	19	49				
SRS	132	126	15	15	8	23				
FFDM	158	135	14	38	13	28				
Diagnostic Certainty	Not at all		Somehow Certain		Average		Almost Certain		Completely Certain	
Observer	1	2	1	2	1	2	1	2	1	2
Tomosynthesis	21	19	12	6	15	22	40	46	128	123
SRS	61	53	21	12	22	26	59	40	53	85
FFDM	32	23	13	19	18	34	61	53	92	87
Lesion Visibility	0%		0□10%		10□50%		50□90%		90□100%	
Observer	1	2	1	2	1	2	1	2	1	2
Tomosynthesis	22	16	15	18	13	24	34	40	132	118
SRS	60	50	20	51	26	50	65	35	45	30
FFDM	32	21	15	27	18	40	57	60	94	68
Spiculation visibility	Not visible		Partially visible		Completely visible		No spiculations			
Observer	1	2	1	2	1	2	1	2		
Tomosynthesis	1	8	23	30	45	103	147	75		
SRS	11	32	43	68	3	5	159	111		
FFDM	5	31	54	67	9	42	148	76		
Calcifications	Present		Less visible		Equally visible		More visible			
Observer	1	2	1	2	1	2	1	2		
Tomosynthesis	48	53	4	13	25	30	19	10		
SRS	47	41	40	30	7	9	0	2		
FFDM	49	53	18	28	28	21	3	4		

FFDM = full-field digital mammography; SRS = specimen radiography system

ography.^{4,5} BCS is not specifically limited based on cut-off values for tumour size; instead, surgeons should balance their decision between the assessed tumour size and the total breast volume. More intraoperative tissue sampling – such as shaving the resection margins after lumpectomy in certain situations or oncoplastic BCS techniques – may help reduce the rate of reoperation.^{5,20} In this study, the reoperation rate was low, which is presumably multifactorial. All preoperative imaging findings were re-evaluated by specialist breast radiologists and multidisciplinary specialists. Every effort was made to evaluate the tumour extent preoperatively and to transfer these findings to the surgical position by ink-marking the skin. Furthermore, all procedures were standardised, including tumour localisation, macroscopic resection margins of ≥ 1 cm, en bloc resection for anterior and posterior margins, structured specimen orientation, speci-

men fixation, imaging and structured histopathological reporting. All of these factors might help to reduce positive margins.⁴

The efficacy of specimen mammography for margin assessment is not yet well established. Laws *et al.* reported that the use of any margin assessment technique did not improve margin status compared with guidewire localisation alone.²¹ According to a meta-analysis, specimen radiography to assess the surgical margin had lower sensitivity than frozen sections (53% *vs.* 86%, respectively).²² However, frozen section is a resource-demanding procedure, is not always readily available and it might prolong the duration and cost of surgery. By contrast, intraoperative imaging is simple, rapid and readily available. In our opinion, its lower accuracy is due mainly to the inability to comprehensively evaluate the microscopic tumour extension from the target lesion. Mammography

TABLE 5. Diameters of the excised lesions evaluated by the two observers using three imaging modalities and in the final pathology report

Lesion diameter	Mean (mm)	Median (mm)	Minimum (mm)	Maximum (mm)	Pearson's coefficient (r)
Observer 1					
Tomosynthesis	16.82	12.70	2.90	84.10	0.471
SRS	17.45	13.90	2.10	96.90	0.421
FFDM	16.96	12.60	2.00	90.10	0.452
Observer 2					
Tomosynthesis	23.04	19.00	4.00	88.00	0.614
SRS	21.31	17.00	5.00	97.00	0.457
FFDM	20.21	15.00	3.00	95.00	0.550
Final Pathology					
	15.69	14.00	0	70	

FFDM = full-field digital mammography; SRS = specimen radiography system

tends to underestimate the size of DCIS and, although the sensitivity of specimen imaging is higher for invasive cancers, it is lower for DCIS.²³ A greater resection margin threshold may reduce the risk of missing a positive margin but increases unnecessary resection of healthy tissue.²³ Mazouni *et al.* determined the sensitivity and specificity of different radiological threshold values (1, 5 and 10 mm), and found that the 10 mm threshold value had the highest sensitivity (75%).²⁴ Britton *et al.* reported that a maximum distance of ≥ 11 mm from the lesion to the specimen edge was associated with a 77% likelihood of having a clear final histological margin.²⁵ Leung *et al.* reported that a 15 mm radiological margin showed the highest combination of sensitivity and specificity for predicting a positive margin.²⁶ DCIS is often associated with invasive cancer and, in this study, half of the specimens included DCIS components. Therefore, the consistent wide macroscopic resection margins in this study presumably contributed to the microscopically clear margins.

It is difficult to directly compare the results of studies assessing the clinical value of specimen radiography because of marked heterogeneity in the study designs and inclusion criteria, as well as the methodology and terminology used, thus making comparisons inconclusive.²⁷ Inconsistencies may be due to different imaging protocols, specimen compression, selective inclusion of patients with different stages of cancer, inclusion of mainly invasive or DCIS patients and the definitions of the outcome measures.^{27,28} In this study, we sought to include all consecutive patients treated at our

institution. We excluded only those patients who underwent BCS after neoadjuvant therapy because some of these patients only have residual microscopic disease or marking clips. Therefore, the patient population in this study closely represents clinical practice at a specialist tertiary hospital.

This study has limitations to consider. This was a single-centre study and the analysis was performed retrospectively. The observers had varying years of experience, which may contribute to the interobserver variability and is consistent with a previous report.²⁹ Furthermore, we could not perform more extensive analysis of the diagnostic accuracy of each method in the evaluation of margins owing to complete primary resection of the lesions without positive margins for malignant lesions. Regardless of these limitations, we analysed a cohort of consecutive patients, which is consistent with and representative of actual clinical practice. Moreover, we included 216 specimens from 204 patients, a considerably larger cohort than most of the related studies reported to date. We also performed three different imaging modalities for each specimen, which allowed us to directly compare radiographs obtained in the same orientation for all imaging methods and thus remove some potential sources of error.

In conclusion, tomosynthesis was superior to SRS and FFDM for the detection and evaluation of target breast lesions, and detected spiculations and calcifications. Therefore, tomosynthesis was more reliable than other intraoperative imaging modalities for evaluating complete excision of breast lesions.

Acknowledgement

This work was supported in part by a grant (to AM and MS) from Kuopio University Hospital (VTR grant 5063573). The authors declare no relationships with any companies, whose products or services may be related to the subject matter of the article. The funding sources were not involved in study design, data collection or analysis, preparation of the manuscript or the decision to submit the manuscript.

References

- Fisher B, Anderson S, Bryant J, Margolese RG, Deutsch M, Fisher ER, et al. Twenty-year follow-up of a randomized trial comparing total mastectomy, lumpectomy, and lumpectomy plus irradiation for the treatment of invasive breast cancer. *N Engl J Med* 2002; **347**: 1233-41. doi: 10.1056/NEJMoa022152
- Veronesi U, Cascinelli N, Mariani L, Greco M, Saccocci R, Luini A, et al. Twenty-year follow up of a randomized study comparing breast-conserving surgery with radical mastectomy for early breast cancer. *N Engl J Med* 2002; **347**: 1227-32. doi: 10.1056/NEJMoa020989
- Houssami N, Macaskill P, Marinovich ML, Morrow M. The association of surgical margins and local recurrence in women with early-stage invasive breast cancer treated with breast-conserving therapy: a meta-analysis. *Ann Surg Oncol* 2014; **21**: 717-30. doi: 10.1245/s10434-014-3480-5
- Landercasper J, Borgert AJ, Fayanjou OM, Cody H 3rd, Feldman S, Greenberg C, et al. Factors associated with reoperation in breast-conserving surgery for cancer: a prospective study of American Society of Breast Surgeon Members. *Ann Surg Oncol* 2019; **26**: 3321-36. doi: 10.1245/s10434-019-07547-w
- McEvoy MP, Landercasper J, Naik HR, Feldman S. Update of the American Society of Breast Surgeons Toolbox to address the lumpectomy reoperation epidemic. *Gland Surg* 2018; **7**: 536-53. doi: 10.21037/gs.2018.11.03
- Mall S, Lewis S, Brennan P, Noakes J, Mello-Thoms C. The role of digital breast tomosynthesis in the breast assessment clinic: a review. *J Med Radiat Sci* 2017; **64**: 203-211. doi: 10.1002/jmrs.230
- Polat YD, Taşkın F, Çıldağ MB, Tanyeri A, Soyder A, Ergin F. The role of tomosynthesis in intraoperative specimen evaluation. *Breast J* 2018; **24**: 992-6. doi: 10.1111/tbj.13070
- Urano M, Shiraki N, Kawai T, Goto T, Endo Y, Yoshimoto N, et al. Digital mammography versus digital breast tomosynthesis for detection of breast cancer in the intraoperative specimen during breast-conserving surgery. *Breast Cancer* 2016; **23**: 706-11. doi: 10.1007/s12282-015-0628-5
- Romanucci G, Mercogliano S, Carucci E, Cina A, Zantedeschi E, Caneva A, et al. Diagnostic accuracy of resection margin in specimen radiography: digital breast tomosynthesis versus full-field digital mammography. *Radiol Med* 2021; **126**: 768-773. doi: 10.1007/s11547-021-01337-9
- Schulz-Wendtland R, Dilbat G, Bani M, Fasching PA, Lux MP, Wenkel E, et al. Full field digital mammography (FFDM) versus CMOS technology versus tomosynthesis (DBT) – which system increases the quality of intraoperative imaging? *Geburtshilfe Frauenheilkd* 2012; **72**: 532-8. doi: 10.1055/s-0032-1314942
- Garlaschi A, Fregatti P, Oddone C, Friedman D, Houssami N, Calabrese M, et al. Intraoperative digital breast tomosynthesis using a dedicated device is more accurate than standard intraoperative mammography for identifying positive margins. *Clin Radiol* 2019; **74**: 974.e1-e6. doi: 10.1016/j.crad.2019.08.004
- Partain N, Calvo C, Mokdad A, Colton A, Pouns K, Clifford E, et al. Differences in re-excision rates for breast-conserving surgery using intraoperative 2D versus 3D tomosynthesis specimen radiograph. *Ann Surg Oncol* 2020; **27**: 4767-76. doi: 10.1245/s10434-020-08877-w
- Park KU, Kuerer HM, Rauch GM, Leung JWT, Sahin AA, Wei W, et al. Digital breast tomosynthesis for intraoperative margin assessment during breast-conserving surgery. *Ann Surg Oncol* 2019; **26**: 1720-8. doi: 10.1245/s10434-019-07226-w
- Wang Y, Ebuoma L, Saksena M, Liu B, Specht M, Rafferty E. Clinical evaluation of a mobile digital specimen radiography system for intraoperative specimen verification. *AJR Am J Roentgenol* 2014; **203**: 457-62. doi: 10.2214/AJR.13.11408
- Miller CL, Coopey SB, Rafferty E, Gadd M, Smith BL, Specht MC. Comparison of intra-operative specimen mammography to standard specimen mammography for excision of non-palpable breast lesions: a randomized trial. *Breast Cancer Res Treat* 2016; **155**: 513-9. doi: 10.1007/s10549-016-3700-8
- Mariscotti G, Durando M, Pavan LJ, Tagliafico A, Campanino PP, Castellano I, et al. Intraoperative breast specimen assessment in breast conserving surgery: comparison between standard mammography imaging and a remote radiological system. *Br J Radiol* 2020; **93**: 20190785. doi: 10.1259/bjr.20190785
- Sardanelli F, Boetes C, Borisch B, Decker T, Federici M, Gilbert FJ, et al. Magnetic resonance imaging of the breast: recommendations from the EUSOMA working group. *Eur J Cancer* 2010; **46**: 1296-316. doi: 10.1016/j.ejca.2010.02.015
- Joukainen S, Okuma H, Kaarela O, Laaksonen E, Kärjä V, Vanninen R, et al. Can supine breast magnetic resonance imaging help hit the target in extreme oncoplastic surgery? *Eur J Surg Oncol* 2021; **47**: 2788-96. doi: 10.1016/j.ejso.2021.07.027
- Amer HA, Schmitzberger F, Ingold-Heppner B, Kussmaul J, El Tohamy MF, Tantawy HI, et al. Digital breast tomosynthesis versus full-field digital mammography – which modality provides more accurate prediction of margin status in specimen radiography? *Eur J Radiol* 2017; **93**: 258-64. doi: 10.1016/j.ejrad.2017.05.041
- Chen JY, Huang YJ, Zhang LL, Yang CQ, Wang K. Comparison of oncoplastic breast-conserving surgery and breast-conserving surgery alone: a meta-analysis. *J Breast Cancer* 2018; **21**: 321-29. doi: 10.4048/jbc.2018.21.e36
- Laws A, Brar MS, Bouchard-Fortier A, Leong B, Quan ML. Intraoperative margin assessment in wire-localized breast-conserving surgery for invasive cancer: a population-level comparison of techniques. *Ann Surg Oncol* 2016; **23**: 3290-6. doi: 10.1245/s10434-016-5401-2
- St John ER, Al-Khudairi R, Ashrafian H, Athanasiou T, Takats Z, Hadjiminas DJ, et al. Diagnostic accuracy of intraoperative techniques for margin assessment in breast cancer surgery: a meta-analysis. *Ann Surg* 2017; **265**: 300-10. doi: 10.1097/SLA.0000000000001897
- Versteegden DPA, Keizer LGG, Schlooz-Vries MS, Duijm LEM, Wauters CAP, Strobbe LJA. Performance characteristics of specimen radiography for margin assessment for ductal carcinoma in situ: a systematic review. *Breast Cancer Res Treat* 2017; **166**: 669-79. doi: 10.1007/s10549-017-4475-2
- Mazouni C, Rouzier R, Balleyguier C, Sideris L, Rochard F, Delaloue S, et al. Specimen radiography as predictor of resection margin status in non-palpable breast lesions. *Clin Radiol* 2006; **61**: 789-96. doi: 10.1016/j.crad.2006.04.017
- Britton PD, Sonoda LI, Yamamoto AK, Koo B, Soh E, Goud A. Breast surgical specimen radiographs: how reliable are they? *Eur J Radiol* 2011; **79**: 245-9. doi: 10.1016/j.ejrad.2010.02.012
- Leung BST, Wan AYH, Au AKY, Lo SSW, Wong WWC, Khoo JLS. Can intraoperative specimen radiograph predict resection margin status for radio-guided occult lesion localisation lumpectomy for ductal carcinoma in situ presenting with microcalcifications? *Hong Kong J Radiol* 2015; **18**: 11-21. doi: 10.12809/hkjr.1414265
- Williams D, McCormack S. Intraoperative mammography for breast cancer surgery: a review of clinical effectiveness, cost-effectiveness, and guidelines [Internet]. Ottawa (ON): Canadian Agency for Drugs and Technologies in Health; 2019. [cited 2022 Apr 15]. PMID: 31411841. Available at: <https://pubmed.ncbi.nlm.nih.gov/31411841/>
- Butler-Henderson K, Lee AH, Price RI, Waring K. Intraoperative assessment of margins in breast conserving therapy: a systematic review. *Breast* 2014; **23**: 112-9. doi: 10.1016/j.breast.2014.01.002
- Mario J, Venkataraman S, Fein-Zachary V, Knox M, Brook A, Slanetz P. Lumpectomy specimen radiography: does orientation or 3-dimensional tomosynthesis improve margin assessment? *Can Assoc Radiol J* 2019; **70**: 282-91. doi: 10.1016/j.carj.2019.03.005