

Cardiac myxoma: single tertiary centre experience

Polona Kacar^{1,2}, Nejc Pavsic^{1,2}, Mojca Bervar^{1,2}, Zvezdana Dolenc Strazar³, Vesna Zadnik⁴, Matija Jelenc⁵, Katja Prokselj^{1,2}

¹ Department of Cardiology, University Medical Center Ljubljana, Ljubljana, Slovenia

² Faculty of Medicine, University of Ljubljana, Ljubljana, Slovenia

³ Institute of Pathology, Faculty of Medicine, University of Ljubljana, Ljubljana, Slovenia

⁴ Epidemiology and Cancer Registry, Institute of Oncology Ljubljana, Ljubljana, Slovenia

⁵ Department of Cardiovascular Surgery, University Medical Center Ljubljana, Ljubljana, Slovenia

Radiol Oncol 2022; 56(4): 535-540.

Received 24 Jun 2022

Accepted 12 Sep 2022

Correspondence to: Assist. prof. Katja Prokselj, M.D., Ph.D., Department of Cardiology, University Medical Center Ljubljana, Zaloška cesta 7, 1525 Ljubljana, Slovenia. E-mail: katja.prokselj@gmail.com

Disclosure: No potential conflicts of interest were disclosed.

This is an open access article distributed under the terms of the CC-BY license (<https://creativecommons.org/licenses/by/4.0/>).

Background. Although cardiac myxoma (CM) are rare and benign, they can cause life-threatening complications, such as hemodynamic disturbances or embolization. Surgical excision of the tumour is the treatment of choice. The aim of the study was to evaluate the epidemiological characteristics, clinical presentation, imaging findings, and outcomes of surgical treatment of patients with CM treated in the largest tertiary care centre in Slovenia.

Patients and methods. We retrospectively analysed the medical records of all patients referred to our institution between January 2005 and December 2020 and identified 39 consecutive adult patients with pathologically confirmed CM.

Results. The average annual incidence of CM in the study was 3 per 2 million population per year. Patients were more often female ($n = 25$, 64%). The mean age at diagnosis was 63.1 ± 13.6 years. Dyspnoea was the most common presenting symptom (31%). CM was an incidental finding in 11 patients (28%). Seven patients presented with thromboembolic event (18%). Transthoracic echocardiography (TTE) was performed in all patients, however additional imaging was required in 22 patients (56%). All patients in our series were successfully treated surgically without in-hospital mortality. During the follow-up period (6 months to 16 years) three patients (8%) died, and all deaths were unrelated to CM. There was no recurrence of CM during the follow-up.

Conclusions. Our single-centre study confirms that CM is rare cardiac tumour with diverse clinical presentation. Our data shows data that CM might be more prevalent than considered before. Surgical resection of the tumour is safe with excellent short- and long-term outcomes.

Key words: cardiac myxoma; cardiac tumours; echocardiography

Introduction

Cardiac tumours are rare and usually benign.¹⁻³ Cardiac myxoma (CM) is the most common benign cardiac tumour in adults and accounts for 50% of all primary cardiac tumors.⁴ The estimated incidence is 0.5–1 cases per million population per year.⁵ The average age of diagnosis is between the

fourth and sixth decade of life, with female preponderance (the female-to-male ratio is approximately 2:1), but myxomas can be diagnosed at any age.^{5,6} Nowadays, CM are detected more frequently due to the increasing availability of multimodality imaging.

Although CM is benign in nature, it can lead to life-threatening complications such as sys-

temic embolisms or hemodynamic disturbances. The clinical presentation of CM is highly variable and is determined by size, location, and mobility of the tumour. The classic triad of CM includes embolic, obstructive cardiac, and constitutional symptoms.⁵⁻⁷ Systemic, cerebral, or pulmonary embolization may be the first symptom of CM.^{7,8} Obstructive cardiac symptoms include dyspnoea, syncope, arrhythmias, heart failure, or sudden cardiac death and are caused by obstruction of the heart valve or heart chamber.⁹ Constitutional symptoms are nonspecific and include fever, weight loss, malaise, myalgia, and muscle weakness. Up to 30% of patients are asymptomatic and CM is an incidental finding.^{3,6,8} Prompt and correct diagnosis is essential because of the potentially life-threatening complications and the different treatment options for different cardiac masses.

Transthoracic echocardiography (TTE) is the diagnostic method of choice.^{6,7} TTE is used to determine the size and location of a CM, its point of attachment, morphology, mobility, and relationship to neighbouring structures. CM are typically located in the left atrium, attached to the atrial septum in the region of the fossa ovalis.⁵ Size and appearance vary considerably. They can reach a diameter of more than 10 cm and occupy the entire cardiac chamber.⁹ Morphologically, they are classified as polypoid or papillary.^{6,8} Multimodality imaging is considered when CM cannot be reliably assessed with TTE, usually due to poor acoustic window or atypical presentation.^{10,11} A definite diagnosis can only be made by histopathological evaluation, which is the gold standard of CM diagnosis.⁷

Surgical excision of CM is the treatment of choice and is usually curative.^{7,12,13} Because of potential serious complications of CM, surgery should be performed without delay. The short- and long-term prognosis is excellent.^{12,14,15} Tumour recurrence is rare.^{6,12}

As CM is rare, most data are based on small single centre studies. Furthermore, there are no data on cardiac myxomas in Slovenia. Therefore, the aim of the study was to evaluate epidemiological characteristics, clinical presentation, diagnostic findings, and outcomes of surgical treatment in patients with CM treated in the largest tertiary care centre in Slovenia.

Patients and methods

We retrospectively analysed the medical records of all adult patients (>18 years of age) referred to

TABLE 1. Demographic and clinical characteristics

Characteristic	n (%)
Sex	
Female	25 (64)
Rhythm	
Sinus rhythm	37 (95)
Clinical presentation*	
Dyspnea	12 (31)
Chest pain	6 (15)
Embolism	7 (18)
- Cerebrovascular	6
- Coronary artery	1
Palpitations	1 (3)
Constitutional signs	2 (5)
Asymptomatic	11 (28)

Values are presented as number (percentage). *Patients may report several symptoms

our Department of Cardiology between January 2005 and December 2020 due to suspected CM. Only patients with a pathologically confirmed CM were included in the final analysis and their demographic, clinical, imaging, and surgical characteristics were reviewed.

The study has been performed in accordance with the ethical standards laid down in the 1964 Declaration of Helsinki and its later amendments. The study, protocol number 0120-512/2020-3, has been approved by Slovenian National Ethics Committee on 15.12.2020. Participants gave their informed consent.

Statistical analysis

Continuous variables are presented as mean \pm standard deviation and categorical variables as number and percentage. Continuous variables were tested for normality using Shapiro-Wilk test. Independent Student's t-test was used to compare continuous variables. Statistical analysis was performed by SPSS version 26.0. P value below 0.05 was considered as statistically significant.

Results

During a 16-year period, 39 patients with pathologically confirmed CM were treated at our de-

TABLE 2. Surgical results and follow-up

Characteristic	n (%)
Location	
- Left atrium	33 (85)
- Right atrium	6 (15)
Post-operative complications	
- Arrhythmia*	6 (86)
- Pleural effusion*	1
- Surgical site infection	1

*One patient suffered from both arrhythmia and pleural effusion. Values are presented as number (percentage).

partment. Of these, 25 were female (64%) and the mean age at diagnosis was 63.1 ± 13.6 years (Table 1). Most patients ($n = 37$, 95%) were in sinus rhythm on admission. We diagnosed an average of three CM per year, with an increase in recent years (Figure 1).

Clinical presentation

The majority of patients were symptomatic (72%). The most common presenting symptoms were dyspnoea (31%) and chest pain (15%) (Table 1). In 11 patients (28%), CM was an incidental finding on TTE or chest computed tomography (CT) performed for other indications. Seven patients (18%) presented with thromboembolic events (four with stroke, two with central retinal artery occlusion, and one with acute coronary syndrome due to coronary artery embolism). Two patients (5%) presented with constitutional signs and symptoms such as fever and fatigue, and one patient complained of palpitations.

Diagnostic methods

TTE was performed in all patients (Figure 2). Additional imaging was performed in 22 patients (56%), either due to suboptimal image quality of TTE or due to atypical location of the tumour. Cardiac magnetic resonance (CMR) was performed most frequently ($n = 15$, 68%) (Figure 3), followed by transoesophageal echocardiography (TEE) ($n = 9$, 41%) and computed tomography (CT) ($n = 2$, 9%).

The average size of CM was 31.9 ± 18.4 mm (range: 10–81 mm). They were most commonly located in LA attached either to the interatrial septum, atrial wall or to the mitral valve ($n = 33$,

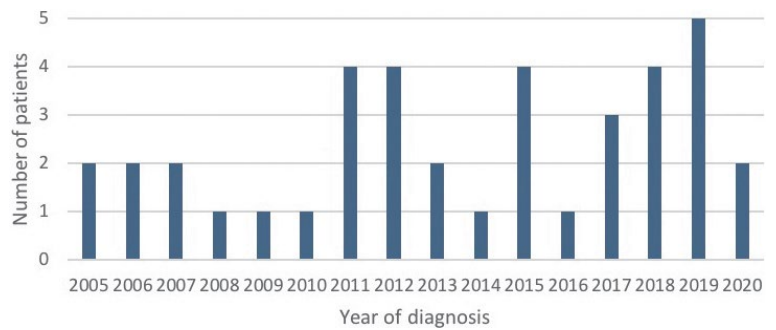


FIGURE 1. Distribution of patients diagnosed per year.

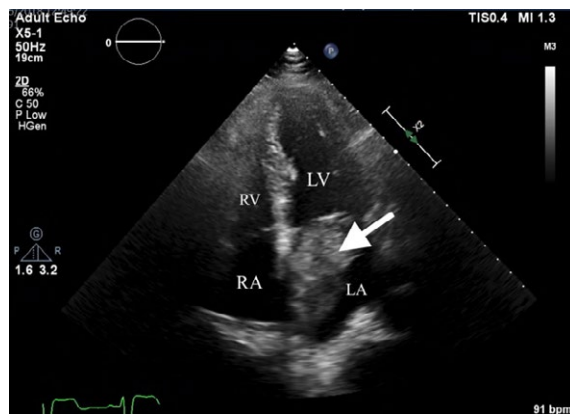


FIGURE 2. Transthoracic echocardiography, apical 4-chamber view. Cardiac mass in left atrium is attached to the interatrial septum in the region of the fossa ovalis (arrow). Histopathological characterization confirmed cardiac myxoma.

LA = left atrium, LV = left ventricle; RA = right atrium; RV = right ventricle

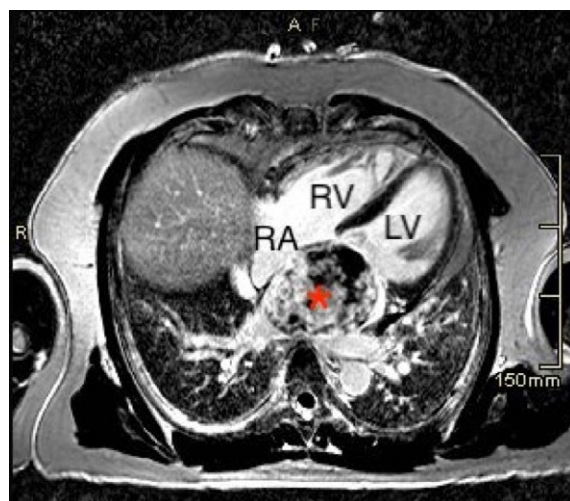


FIGURE 3. Cardiac magnetic resonance, late gadolinium enhancement, 4-chamber view. Asterisk – Large mass occupying the entire left atrium with heterogeneous pattern of enhancement, consistent with cardiac myxoma.

LV = left ventricle; RA = right atrium; RV = right ventricle

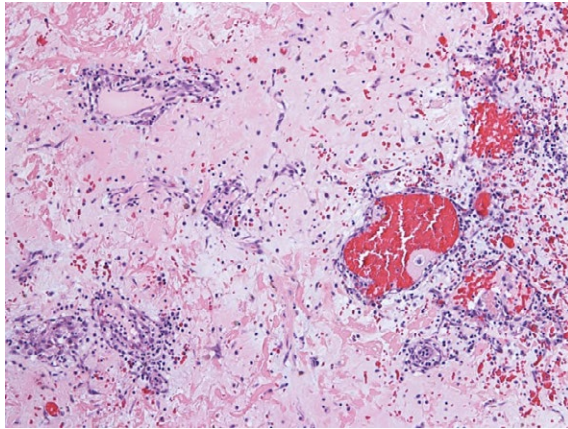


FIGURE 4. Abundant myxoid stroma with clusters of myxoma cells forming cords and ring structures (HE 100x).

85%), followed by RA (n = 6, 15%). Most CM did not cause left ventricular inflow obstruction (n = 27, 69%). Asymptomatic CM were smaller than symptomatic CM (30.2 ± 14.1 vs 41 ± 19.2 mm, p = 0.09).

Surgical treatment and follow-up

All tumours were successfully surgically resected (Figure 5). CM was most commonly located in the left atrium (n = 33, 85%) (Table 2). The diagnosis was confirmed histologically in all patients (Figure 4). The average length of hospital stay was 9 ± 4.8 days. No patient died during hospitalization. Two patients were readmitted within 30 days, one due to surgical site infection and one due to fever. Perioperative complications occurred in seven patients (18%), most commonly arrhythmias (86%), one patient had pleural effusion and one had surgical site infection.

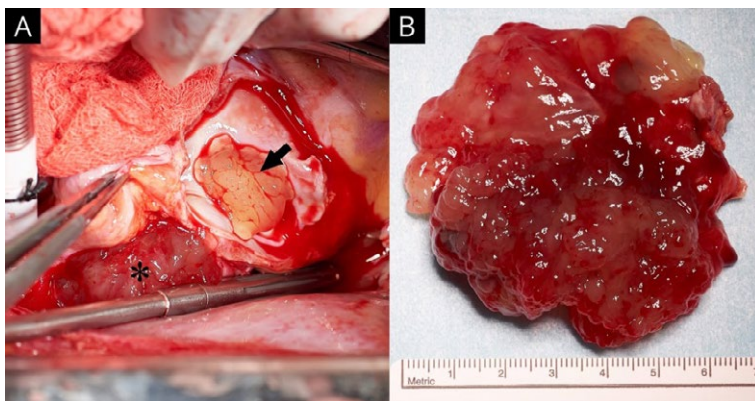


FIGURE 5. (A) Intraoperative view of myxoma protruding through fossa ovalis with its smaller part in the right atrium (arrow) and larger part in left atrium (asterisk). (B) The left atrial part of the myxoma.

The mean follow-up period was 7.6 years (range between 6 months and 16 years). There was no recurrence of CM on follow-up. Three patients (8%) died, but the cause of death was not related to CM.

Discussion

We present 16 years' experience in the treatment of patients with CM at the largest tertiary centre in Slovenia. CM is rare. In the study, the average annual incidence of CM was 3 per 2 million population per year, which is higher compared to other older series.^{5,16-18} Some studies used earlier data, before the era of expansion of cardiac imaging, which may explain the differences in reported incidences.^{5,16-18} We have diagnosed more patients in recent years, which is probably due to the increase in diagnostic procedures used for various indications. Similarly was shown in other previous studies.^{5,16-18} In Slovenia, cardiovascular surgery is performed in two other institutions, where some of the patients with CM may also have been operated. Therefore, we can assume that the cumulative annual incidence of CM in Slovenia is higher than the one reported in our study.

CM is more common in women than in men, which was also confirmed in our series.¹³ The mean age at diagnosis was 63.1 ± 13.6 years, which is comparable to other reports.^{8,9}

The clinical presentation of CM depends on the size, location and mobility of the tumour and can be divided into three groups: obstructive cardiac (dyspnoea, arrhythmia, palpitations, syncope), embolic and constitutional symptoms.⁷ In our group, dyspnoea was the most common presenting symptom (31%), followed by chest pain (15%). This is comparable to other studies that reported dyspnoea as the most common symptom.^{6,8,19} None of the patients showed signs of overt heart failure. Similar to other studies, we observed embolic events in 18% of patients, which were either cerebrovascular or acute coronary syndrome. CM are gelatinous and friable, therefore such a manifestation is not surprising.^{6,7,19} Smaller tumours and those with villous surface are more prone to embolic manifestations than those with smooth surface.^{7,19} Frequent embolic events emphasize the need for timely diagnosis and prompt surgical treatment of CM. Constitutional symptoms occurred in only 5% of patients, which is lower than in other studies, however they may be underreported due to the retrospective design of our study or disregarded by patients themselves.^{6,13} Incidental finding of CM on

different imaging modalities is not uncommon, as was the case in nearly one-third of patients (28%) in our series. Similar findings have been reported in other studies.²⁰ Asymptomatic CM are usually smaller than symptomatic CM, which was also observed in our study.¹⁹

Due to the nonspecific clinical presentation, cardiac imaging is crucial in the evaluation of patients with suspected CM. Although all our patients underwent TTE, additional imaging was performed in 56%, most commonly CMR (68%). TTE is the most common first diagnostic method of choice with 90–96% accuracy in diagnosing CM.^{5,7,10} With TTE we can determine tumour size, location, morphology, mobility, and association with neighbouring structures. In patients with poor acoustic windows or atypical presentation, multimodality imaging is recommended.¹⁰ TEE provides superior image resolution and better visualization of CM.^{10,11} CT and CMR provide additional information on tissue characteristics and topographic relationships.^{21,22} This information is important in deciding on the mode and extent of treatment.

Surgical resection of CM is the treatment of choice. It is associated with a low rate of postoperative complications. The 30-day mortality rate after CM excision ranges from 0% to 10%.²³ The most common postoperative complications are arrhythmias.⁵ All patients in our study underwent surgical resection of CM. It has been a long-standing practice at our institution to operate on patients promptly after diagnosis to prevent possible life-threatening complications such as cerebral and coronary embolisms or valve obstruction. In the study, no patient died and only seven patients (18%) suffered from mild postoperative complications. The recurrence rate after CM resection has been reported to be less than 10%.^{19,24,25} Follow-up in our study showed an excellent outcome after surgery without recurrence of CM. None of the reported deaths were related to the diagnosis or treatment of CM.

The study shows that the outcomes in our patients are comparable to those reported in other studies. We therefore conclude that the management of patients with CM in Slovenia is comparable to that in established international centres.

The retrospective nature of this study and a relatively small study population are the main limitations of this study. However, the population size is comparable to other studies on CM, reflecting the paucity of cases. This limitation could only be overcome by large multicentre studies, which could provide a larger study population.

Conclusions

CM are rare but the most common primary cardiac tumours. An average of three patients are diagnosed yearly at our tertiary institution, indicating a higher average annual incidence than reported in previous studies. Although benign, CM can lead to life-threatening complications. Therefore, correct and timely diagnosis, which often requires multimodality imaging, is crucial. Surgical resection of CM with pathohistological confirmation is the treatment of choice and should be performed promptly. Surgical and follow-up outcomes at our tertiary centre are excellent, without CM related short- or long-term mortality and a low rate of postoperative complications.

Acknowledgments

The study was financially supported by the Slovenian Research Agency - research core funding No. P3-0429, Slovenian research programme for comprehensive cancer control SLORApr.

References

- Butany J, Leong SW, Carmichael K, Komeda M. A 30-year analysis of cardiac neoplasms at autopsy. *Can J Cardiol* 2005; **21**: 675-80. PMID: 16003450
- Cresti A, Chiavarelli M, Glauber M, Tanganelli P, Scalese M, Cesareo F, et al. Incidence rate of primary cardiac tumors: a 14-year population study. *J Cardiovasc Med* 2016; **17**: 37-43. doi: 10.2459/JCM.0000000000000059
- Tyebally S, Chen D, Bhattacharyya S, Mughrabi A, Hussain Z, Manisty C, et al. Cardiac tumors JACC cardiooncology state-of-the-art review. *Jacc Cardiooncology* 2020; **2**: 1-19. doi: 10.1016/j.jacc.2020.05.009
- Poterucha TJ, Kochav J, O'Connor DS, Rosner GF. Cardiac tumors: clinical presentation, diagnosis, and management. *Curr Treat Options Oncol* 2019; **20**: 1-15. doi: 10.1007/s11864-019-0662-1
- Samanidis G, Khoury M, Balanika M, Perrea DN. Current challenges in the diagnosis and treatment of cardiac myxoma. *Kardiol Pol* 2020; **78**: 269-77. doi: 10.33963/KP.15254
- Pinede L, Duhaut P, Loire R. Clinical presentation of left atrial cardiac myxoma: a series of 112 consecutive cases. *Medicine (Baltimore)* 2001; **80**: 159-72. doi: 10.1097/00005792-200105000-00002
- Gribrorio-Guzman AG, Aseyev OI, Shah H, Sadreddini M. Cardiac myxomas: clinical presentation, diagnosis and management. *Heart* 2022; **108**: 827-33. doi: 10.1136/heartjnl-2021-319479
- Lee SH, Park JS, Park JH, Chin JY, Yoon WS, Kim HY, et al. Comparison of clinical and echocardiographic characteristics between cardiac myxomas and masses mimicking myxoma. *Korean Circ J* 2020; **50**: 822-32. doi: 10.4070/KCJ.2020.0024
- Karabinis A, Samanidis G, Khoury M, Stavridis G, Perreas K. Clinical presentation and treatment of cardiac myxoma in 153 patients. *Medicine (Baltimore)* 2018; **97**: e12397. doi: 10.1097/MD.00000000000012397
- Colin GC, Gerber BL, Amzulescu M, Bogaert J. Cardiac myxoma: a contemporary multimodality imaging review. *Int J Cardiovasc Imaging* 2018; **34**: 1789-808. doi: 10.1007/s10554-018-1396-z
- Engberding R, Daniel WG, Erbel R, Kasper W, Lestuzzi C, Curtius JM, et al. Diagnosis of heart tumours by transoesophageal echocardiography: a multicentre study in 154 patients. *Eur Heart J* 1993; **14**: 1223-8. doi: 10.1093/eurheartj/14.9.1223

12. Bjessmo S, Ivert T. Cardiac myxoma: 40 years' experience in 63 patients. *Ann Thorac Surg* 1997; **63**: 697-700. doi: 10.1016/S0003-4975(97)00003-9
13. Centofanti P, Di Rosa E, Deorsola L, Actis Dato GM, Patanè F, La Torre M, et al. Primary cardiac tumors: early and late results of surgical treatment in 91 patients. *Ann Thorac Surg* 1999; **68**: 1236-41. doi: 10.1016/S0003-4975(99)00700-6
14. Hill M, Cherry C, Maloney M, Midyette P. Surgical resection of atrial myxomas. *AORN J* 2010; **92**: 393-409. doi: 10.1016/j.aorn.2010.06.012
15. Garatti A, Nano G, Canziani A, Gagliardotto P, Mossuto E, Frigiola A, et al. Surgical excision of cardiac myxomas: twenty years experience at a single institution. *Ann Thorac Surg* 2012; **93**: 825-31. doi: 10.1016/j.athoracsur.2011.11.009
16. NiDhonnchu T, Daly A, Ogbo S, Keita L, Mulligan N, McCarthy J. 31 Cardiac myxoma in the Republic of Ireland: a national incidence study. [abstract]. *Heart* 2016; **102**: A16-7. doi: 10.1136/heartjnl-2016-310523.31
17. Sigurjonsson H, Andersen K, Gardarsdottir M, Petursdottir V, Klemenzson G, Gunnarsson G, et al. Cardiac myxoma in Iceland: a case series with an estimation of population incidence. *Apmis* 2011; **119**: 611-7. doi: 10.1111/j.1600-0463.2011.02777.x
18. Pérez-Andreu J, Arribas Leal JM, Gervase G, Rivera-Caravaca JM, Cánovas López S, Marín F. Epidemiology of cardiac myxoma in a Spanish population. A 30-year surgical series. *Rev Española Cardiol English Ed* 2019; **72**: 685-6. doi: 10.1016/j.rec.2018.08.021
19. Cianciulli TF, Cozzarin A, Soumoulou JB, Saccheri MC, Méndez RJ, Beck MA, et al. Twenty years of clinical experience with cardiac myxomas: diagnosis, treatment, and follow up. *J Cardiovasc Imaging* 2019; **27**: 37-47. doi: 10.4250/jcvi.2019.27.e7
20. Gui J, Maqsood A, Khadka S, Rodriguez K, Everett G. New trend of cardiac myxoma - case series and systematic review. *Clin Cardiol Cardiovasc Med* 2016; **1**: 1-5. doi: 10.33805/2639.6807.101
21. Wintersperger BJ, Becker CR, Gulbins H, Knez A, Bruening R, Heuck A, et al. Tumors of the cardiac valves: imaging findings in magnetic resonance imaging, electron beam computed tomography, and echocardiography. *Eur Radiol* 2000; **10**: 443-9. doi: 10.1007/s003300050073
22. Mendes GS, Abecasis J, Ferreira A, Ribeiros R, Abecasis M, Gouveia R, et al. Cardiac tumors: three decades of experience from a tertiary center: are we changing diagnostic work-up with new imaging tools? *Cardiovasc Pathol* 2020; **49**: 107242. doi: 10.1016/j.carpath.2020.107242
23. Jones DR, Warden HE, Murray GF, Hill RC, Graeber GM, Cruzavala JL, et al. Biatrial approach to cardiac myxomas: a 30-year clinical experience. *Ann Thorac Surg* 1995; **59**: 851-6. doi: 10.1016/0003-4975(95)00064-R
24. Wu X, Yang D, Yang Z, Li J, Zhao Y, Wang K, et al. Clinical characteristics and long term post-operative outcome of cardiac myxoma. *EXCLI J* 2012; **11**: 240-9. PMID: 27418902
25. Obrenović-Kirčanski B, Mikić A, Parapid B, Djukić P, Kanjuh V, Milić N, et al. A 30-year-single-center experience in atrial myxomas: from presentation to treatment and prognosis. *Thorac Cardiovasc Surg* 2013; **61**: 530-6. doi: 10.1055/s-0032-1322545